

CONTINUING MEDICAL EDUCATION ΣΥΝΕΧΙΖΟΜΕΝΗ ΙΑΤΡΙΚΗ ΕΚΠΑΙΔΕΥΣΗ

Internal Medicine Quiz - Case 1

A 95 year old woman without any previous history of rheumatic disease presented to the outpatient department for evaluation of arthralgias of recent onset (2 days). The affected joints were the left wrist and the right knee joint. This was the first such episode. 6 months before this she had suffered an ischemic cerebrovascular accident that left her immobilized and 7 years ago she underwent a total arthroplasty of the right hip joint for long standing osteoarthritis.

The left wrist joint was enlarged, red and warm with limitation of the range of motion, without any effusion. The right knee joint was also enlarged and had limitation of the range of motion with minimal effusion but no redness. She had no fever and the rest of the physical examination was unremarkable.

Of the laboratory examinations performed the ESR was 60 mm/hr, C-reactive protein was 112 mg/L, the hematocrit was 35,8%, white blood cell count was 11,23 k/μl with 91% neutrophils, platelet count was 204 k/μl, serum urea was 70 mg/dl and creatinine 0,5 mg/dl, serum urate was 3,9 mg/dl and creatine kinase was 22 U/L, while urinalysis, rheumatoid factor, antinuclear antibody testing and serum complement levels were normal.

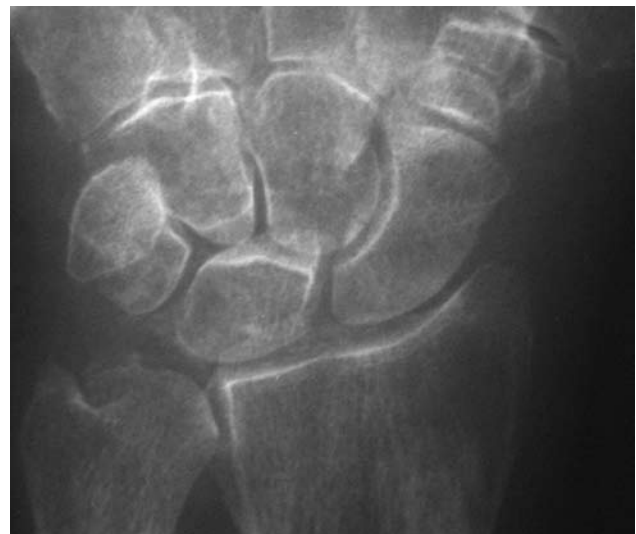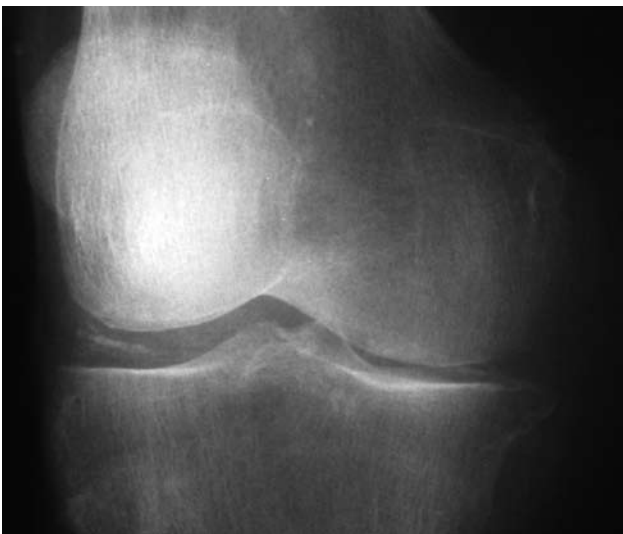
Corresponding author:

C.S Floudas, National and Kapodistrian University of Athens, School of Medicine, First Department of Internal Medicine, Laiko General Hospital, Athens, Greece
e-mail: chfloudas@yahoo.com

ARCHIVES OF HELLENIC MEDICINE 2007, 24(4):403
ΑΡΧΕΙΑ ΕΛΛΗΝΙΚΗΣ ΙΑΤΡΙΚΗΣ 2007, 24(4):403

C.S. Floudas,
T. Ntalageorgos,
P. Konstantopoulou,
G. Vaiopoulos

*First Department of Internal
Medicine, National and Kapodistrian
University of Athens, School of
Medicine, Laiko General Hospital,
Athens, Greece*



Figures 1 and 2 show the X-rays of the affected joints (right knee and left wrist joint respectively).

Diagnosis: Calcium pyrophosphate dihydrate crystal deposition disease (pseudogout).
