

## CONTINUING MEDICAL EDUCATION ΣΥΝΕΧΙΖΟΜΕΝΗ ΙΑΤΡΙΚΗ ΕΚΠΑΙΔΕΥΣΗ

### Internal Medicine Quiz - Case 2

A 62-year-old woman presented to the Emergency Department with a feeling of burn and bloat in upper abdomen, which expanded in chest and anterior neck, accompanied with dysphagia after meals, during the last month. She also states that the last 15 days she has a gorge-rise, spitting out clean saliva, which appears early in the morning, when she wakes up, for which she was prescribed initially with omeprazole, with no result, and then metoclopramide-ranitidine that reduced discomfort frequency. A generalized weakness, lack of appetite and a 5 kg loss of weight is reported during the last month. She reported no any fever or chills since symptoms appeared. The patient has not noticed any remarkable change in her defecations considering the presence of blood, the colour, the frequency or the texture. The patient's medical history is significant for osteoporosis, diagnosed before 4 years, treated by disphosphonates.

On physical examination the patient was awake and uptight. Heart rate was 98 bpm, blood pressure 150/80 mmHg, respiratory rate 18 breaths per minute, temperature 36.4 °C. The patient's heart rhythm was irregular (tachycardia, arrhythmia), no murmurs or gallops. The lungs were clear to auscultation and abdomen was soft, nondistended and painless to pressure, normal bowel sounds. Liver and spleen were normal, no tangible nodes. Skin examination was clear.

Laboratory examinations revealed normal complete blood account (CBC) and normal basic chemistry panel, except from borderline low urea, 16 mg/dL (normal laboratory's range: 17–50 mg/dL). The ECG show supraventricular systoles and LAH, but no evidence of ischemia. A laryngoscopy was normal, without remarkable findings. A radiography (X-ray) of the chest was ordered (figures 1 and 2).

An ultrasonography of the abdomen was performed (liver-spleen-pancreas-gall bladder-biliary ducts), which was normal, except from a lesion in the right hepatic lobe compatible with hemangioma (32,7×24,7 mm). The Mantoux test was negative.

CT scan of chest-abdomen showed a large, orbicular mass (8×8 cm) with definite-smooth borders and heterogeneous structure, in the anterior mediastinum, followed by an atelectasia of the left upper pulmonary lobe (figures 3 and 4). The histological examination revealed diagnosis.

#### Comment

Most radiologists divide the mediastinum into 3 compartments, as proposed by Felson. Anterior mediastinum is bounded anteriorly by the sternum and posteriorly by a line drawn from the anterior aspect of the trachea and along the posterior heart border. Posterior mediastinum is defined by a line that is 1 cm posterior to the anterior edge of the vertebral bodies. Middle compartment lies between anterior and posterior mediastinum. The lesions which may found in posterial mediastinal compartement are shown in figure 5.

Corresponding author:

N. Viniou, First Department of Internal Medicine, "Laiko" General Hospital, Athens, Greece, Tel.: +30210.7462511, Fax: +30210.7788830  
e-mail: jbnv@otenet.gr

ARCHIVES OF HELLENIC MEDICINE 2007, 24(5):513  
ΑΡΧΕΙΑ ΕΛΛΗΝΙΚΗΣ ΙΑΤΡΙΚΗΣ 2007, 24(5):513

N. Viniou,  
J.V. Asimakopoulos,  
C. Bomboris,  
G. Andreopoulos,  
Y. Dalamagas,  
V. Milionis,  
P. Diamantopoulos,  
N. Gratsias,  
M. Aspradaki,  
J. Meletis

First Department of Internal Medicine,  
National and Kapodistrian University  
of Athens, School of Medicine, "Laiko"  
General Hospital, Athens, Greece

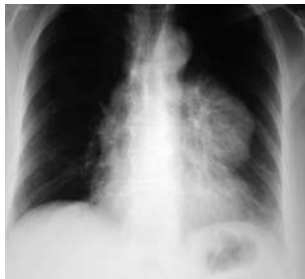

Figure 1

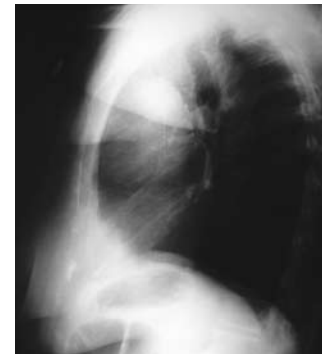

Figure 2

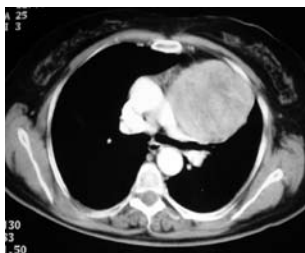

Figure 3

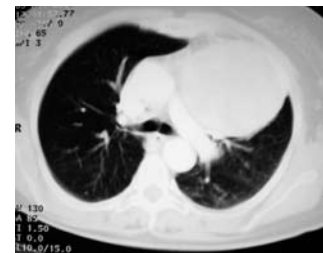

Figure 4

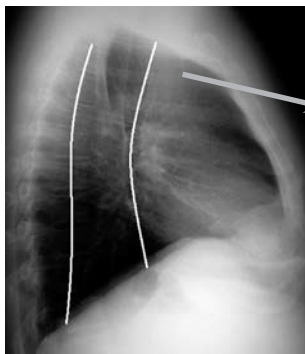


Figure 5

- Anterior mediastinum
1. Thymoma
  2. Aneurysm
  3. Angiomatous tumor
  4. Esophageal tumor
  5. Goiter
  6. Lipoma
  7. Lymphoma
  8. Morgani hernia
  9. Parathyroid tumor
  10. Pericardial cyst
  11. Teratoma
  12. Thyroid tumor

Diagnosis: Thymoma