

CONTINUING MEDICAL EDUCATION ΣΥΝΕΧΙΖΟΜΕΝΗ ΙΑΤΡΙΚΗ ΕΚΠΑΙΔΕΥΣΗ

Vascular Diseases Quiz – Case 7

A 76-year-old man was referred to our hospital for evaluation of an asymptomatic descending thoracic aortic aneurysm (DTAA) diagnosed incidentally following a chest x-ray (fig. 1). His past medical history included hypertension, hyperlipidemia, diabetes and chronic obstructive pulmonary disease (current smoker). He was on antihypertensive and antidiabetic medication. CT angiography and subsequent digital subtraction angiography revealed a right sided 6 cm DTAA associated to a retroesophageal right aortic arch (RAA) and an aberrant left subclavian artery arising from a Kommerell's diverticulum. Arch branches arose irregularly in the following order: left common carotid, right common carotid, right subclavian and left subclavian arteries (fig. 2). (a) What is the RAA classification and what type of arch is the one described? (b) What is the appropriate treatment for this patient?

Comment

Right Aortic Arch (RAA) represents a rare congenital disorder with 0.05–0.1% frequency of occurrence. The co-existence of a retroesophageal aortic segment and an aberrant (retroesophageal) left subclavian artery arising from a Kommerell's diverticulum along with a right descending aorta consist an extremely uncommon vascular malformation.

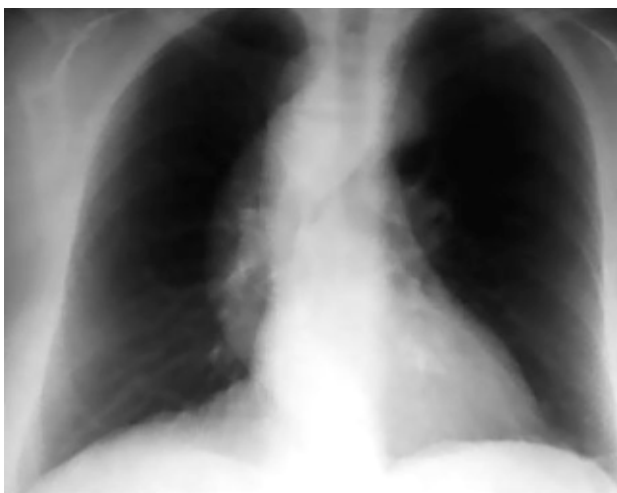


Figure 1. Chest x-ray indicating an aneurysm of the descending aorta.

ARCHIVES OF HELLENIC MEDICINE 2008, 25(4):542–543
ΑΡΧΕΙΑ ΕΛΛΗΝΙΚΗΣ ΙΑΤΡΙΚΗΣ 2008, 25(4):542–543

E. Avgerinos,
A. Mathaiou,
A. Katsargyris,
F. Markatis,
C. Klonaris

¹1st Department of Surgery, Vascular Division, Athens University, Medical School, "Laiko" Hospital, Athens, Greece

The existence of a right aortic arch, that is one passing to the right of the trachea and esophagus is considered to be caused by the development of the fourth right arch rather than the usual left arch. In the majority of the cases of right aortic arch there is a further irregularity affecting the origin of the left subclavian artery which arises as the last branch of arch or first branch of the descending aorta. Many variations occur in the number and position of vessels arising from the aortic arch, one of these similar to the case we herein describe. Noteworthy is the finding of right aortic arch with Kommerell's diverticulum, initially reported in 1936 by Kommerell in a case of an aberrant right subclavian artery originating from the descending thoracic aorta of a left-sided arch and associated with persistence of a remnant of the right dorsal aorta. The latter

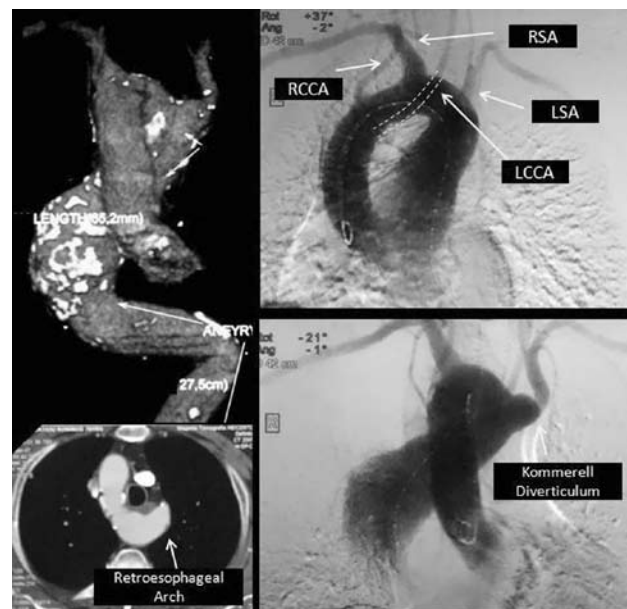


Figure 2. CT angiography and digital subtraction angiography indicating a right sided DTAA associated to a right aortic arch (RAA) with a retroesophageal segment and an aberrant left subclavian artery arising from a Kommerell's diverticulum.

appeared as a diverticulum from which the aberrant right subclavian artery originated. Right aortic arch anomalies have been classified

Table 1. Right aortic arch classification by Gross and Ware

A. Situs Inversus Viscerum

B. Without Inversion

1. Anterior type: The arch is anterior to the trachea and the descending aorta is on the right side
2. Posterior type: The aorta passes to the left behind the esophagus and the descending aorta courses to the right of the normal sided position
 - Right aortic arch in which the subclavian artery arises last from the arch and crosses behind the esophagus to its distribution to the arm
 - Right aortic arch in which no vessel arising from the arch crosses the midline posterior to the esophagus
 - Right aortic arch with a persistent left aortic diverticulum giving origin to the left subclavian artery. No vessel from the arch crosses the midline posteriorly

by various systems. Although the most simplified classification was suggested by Edwards depending upon whether the descending aorta and ductus arteriosus were left or right sided, the one that best suits our case is the classification given by Gross and Ware: right aortic arch without inversion, posterior type, with a persistent left aortic diverticulum giving origin to the left subclavian artery (Type B/2/C) (tab. 1).

As this kind of arches are scarcely encountered only sporadic reports of surgical repair exist. The technical challenges associated with these patients' particular anatomy e.g. pattern of arch vessels, location of descending aorta, relations to esophagus and trachea etc, pose a significant life risk. Endovascular repair in such cases, when technically feasible, emerges as a favorable alternative.

Corresponding author:

C. Klonaris, 1st Department of Surgery, Vascular Division, Athens University, Medical School, "Laiko" General Hospital, 17 Agiou Thoma street, GR-115 27 Athens, Greece
 e-mail: chris_klonaris@yahoo.com

Diagnosis: (a) Right Aortic Arch Classification by Gross and Ware: Right aortic arch without inversion posterior type with a persistent left aortic diverticulum giving origin to the left subclavian artery (Type B/2/C). (b) Endovascular repair