

## CONTINUING MEDICAL EDUCATION ΣΥΝΕΧΙΖΟΜΕΝΗ ΙΑΤΡΙΚΗ ΕΚΠΑΙΔΕΥΣΗ

---

### Internal Medicine Quiz – Case 14

A 68-year-old man was presented to our Hepatology Department for the evaluation of thrombocytopenia and prolonged prothrombin time.

He had an accident (fall on the ground in a slippery room) and had a bruise in his right arm. Initial evaluation showed PLT <100.000 and INR 1.5 and therefore he was advised to seek hepatology counselling.

His general condition was excellent. His vital signs consisted of a body temperature of 36.8 °C, a heart rate of 70 BPM and an arterial blood pressure of 120/70 mmHg. Heart sounds comprised of normal S1–S2 and the auscultation of the thoracic cavity did not reveal any pathological signs. There were no signs of bruises or petechiae, flapping tremor or spiders. There was no parotid enlargement or palmar erythema.

Liver was enlarged, painless with a rigid margin extending 5 cm below the right pleural space. Spleen was not palpable and there were no palpable lymph nodes.

His past medical history was unremarkable besides an episode of bleeding gastric ulcer 15 years ago.

The remainder of the physical examination was otherwise normal.

His blood count was normal (Ht 38% ,WBC 4.400/μL, PLT 166.000/μL) with a normal blood smear and his biochemical tests were also normal (ALT 9 U/L, AST 16 U/L, ALP 172 U/L, γGT 92 U/L, serum albumin 4,8 g/dL). He had a prolonged prothrombin time (PT 16 sec, INR 1.34) and fibrinogen 79 mg/dL. D-dimers were 9.9 mg/dL. Test for hepatitis viruses was negative. X-ray of the abdomen (fig. 1) showed diffuse calcifications in the epigastrium and right upper quadrant. Computed tomography scan of the abdomen showed calcificated cysts in the liver (figures 2, 3, 4). A test for serum echinococcus antibodies was negative. Biopsy

ARCHIVES OF HELLENIC MEDICINE 2009, 26(5):714–715  
ΑΡΧΕΙΑ ΕΛΛΗΝΙΚΗΣ ΙΑΤΡΙΚΗΣ 2009, 26(5):714–715

---

**A.G. Antoniadis,**  
**A. Katsandris,**  
**F. Ntziora,**  
**C. Floudas,**  
**A. Andreopoulos**

---

*First Department of Internal Medicine,  
National and Kapodistrian University  
of Athens, School of Medicine, "Laiko"  
General Hospital, Athens, Greece*

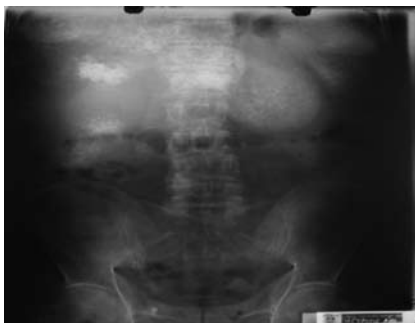

Figure 1

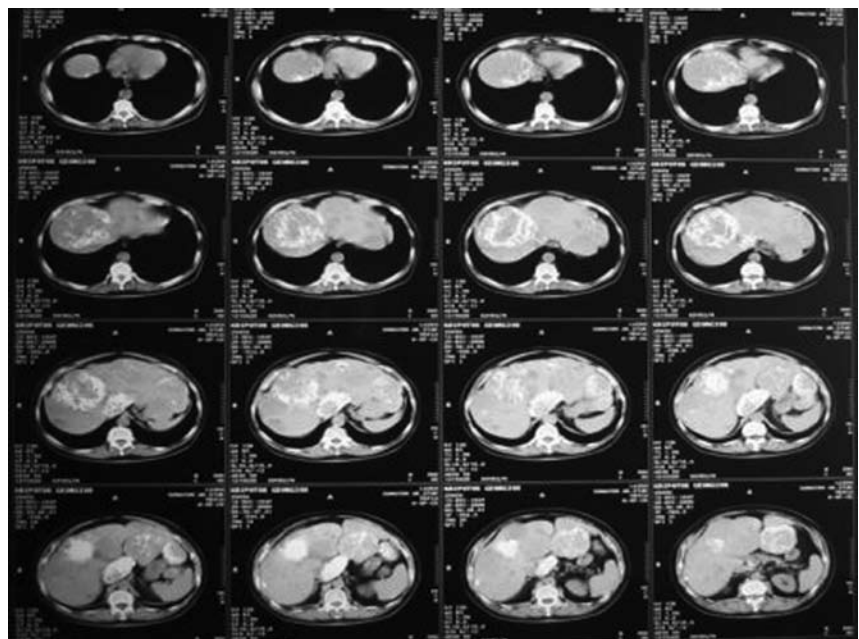


Figure 2

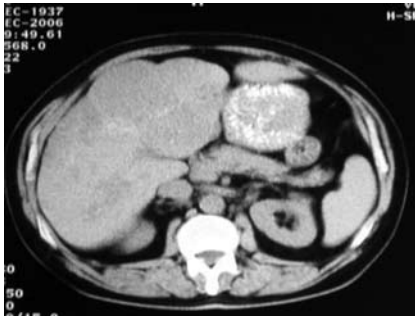

Figure 3

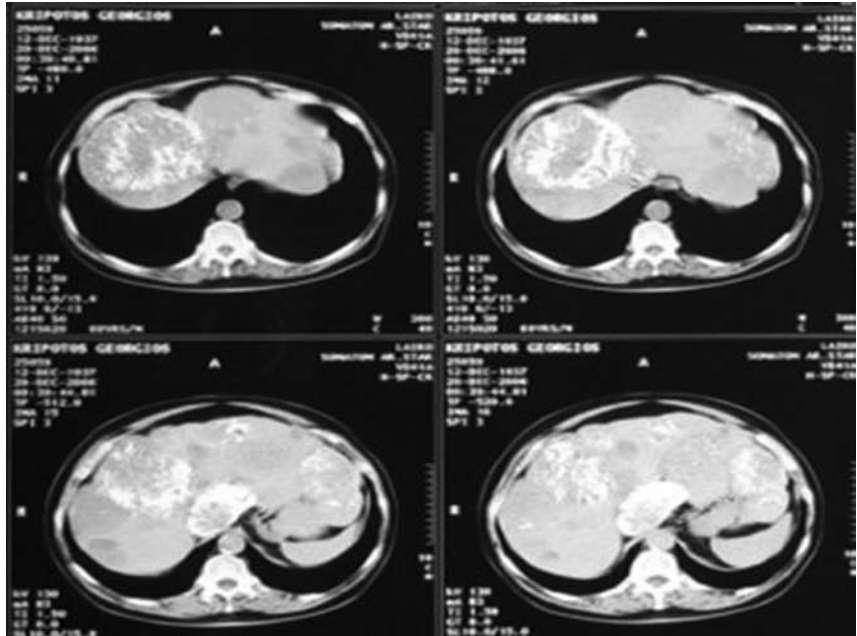


Figure 4

was not conducted due to prolonged prothrombin time.

Corresponding author:

A.G. Antoniadis, First Department of Internal Medicine, National and Kapodistrian University of Athens, School of Medicine, "Lai-ko" General Hospital, Athens, Greece, Tel.: +30 693 69 08 836, Fax: +30 210 7788830  
e-mail: antoniad@med.uoa.gr

**Diagnosis:** Latent diffuse echinococcosis of the liver (calcificated cysts with no living parasites) with mild coagulopathy due to loss of normal hepatocytes