

CONTINUING MEDICAL EDUCATION ΣΥΝΕΧΙΖΟΜΕΝΗ ΙΑΤΡΙΚΗ ΕΚΠΑΙΔΕΥΣΗ

Medical Imaging Quiz – Case 11

A 34-year-old female, non-smoker was presented in the emergency department of our hospital with dyspnea, cough and chest pain. On physical examination the patient presented wheezes and dullness to percussion. Laboratory values were within normal ranges. A reduction in the diffusion capacity of carbon monoxide was the most common initial abnormality. Although chest radiograph findings were normal (fig. 1), CT scan of the lung demonstrated small pleural effusion and pneumothorax of the right lung (fig. 2), while an additional high resolution CT (HRCT) demonstrated bilateral numerous well-defined thin-walled cysts surrounded by normal parenchyma, traction bronchiectasis, honeycombing, airflow obstruction, air trapping, and formation of bullae and pneumothorax. Cysts range from 2 mm to 5 cm in diameter, are round in shape and more or less uniform. Cysts are distributed diffusely throughout the lungs and upper and lower lobes are involved to a similar degree. An open lung biopsy was occurred for accurate diagnosis.

Comment

Lymphangiomyomatosis (LAM) is a rare disorder of unknown

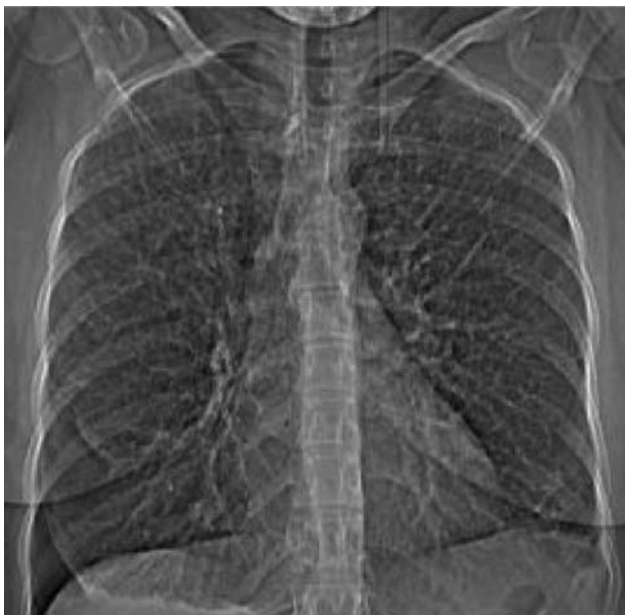

Figure 1. Normal chest radiograph upon admission.

ARCHIVES OF HELLENIC MEDICINE 2010, 27(2):281–282
ΑΡΧΕΙΑ ΕΛΛΗΝΙΚΗΣ ΙΑΤΡΙΚΗΣ 2010, 27(2):281–282

**K. Stathopoulos,
I. Tsagaridou,
N. Ntagiantas,
O. Konstantinopoulos,
L. Thanos**

*Department of Radiology, "Sotiria"
General Hospital of Chest Diseases,
Athens, Greece*

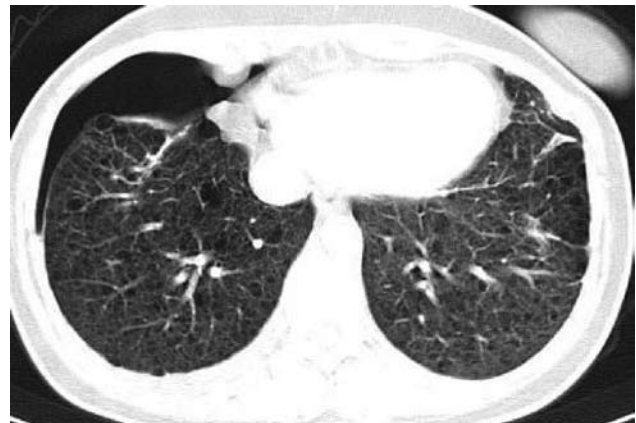

Figure 2. CT scan of the lung demonstrated small pleural effusion and pneumothorax of the right lung.

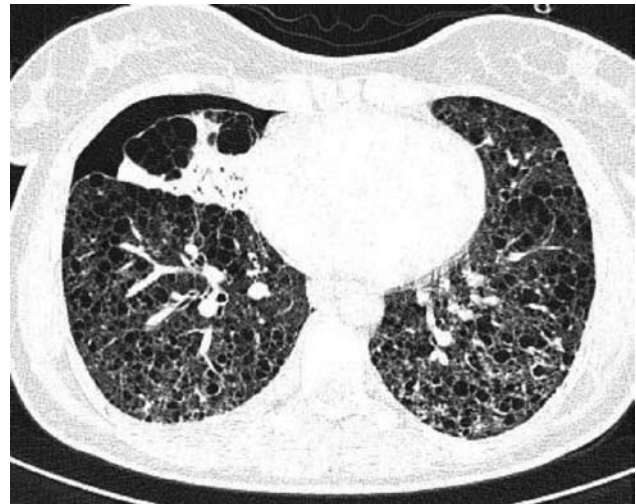


Figure 3. HRCT demonstrated bilateral numerous well-defined thin-walled cysts surrounded by normal parenchyma, traction bronchiectasis, honeycombing, airflow obstruction, air trapping, and formation of bullae and pneumothorax.

cause, resulting from proliferation in the lung, kidney, and axial lymphatics of a neoplastic cell having a smooth muscle cell phenotype (LAM cell). Cystic destruction of the lung with progressive pulmonary dysfunction and the presence of abdominal tumors [eg, angiomyolipomas (AML), lymphangioliomyomas] characterize the disease. LAM primarily is a disease of women of childbearing age, but LAM has been reported in patients aged 12 years to patients older than 70 years; however, rare case reports of LAM in men exist, primarily in men with tuberous sclerosis complex, an inherited disorder having shared features with LAM.

Lymphangioliomyomatosis (LAM) cell proliferation may obstruct bronchioles, possibly leading to airflow obstruction, air trapping, formation of bullae, and pneumothoraces. Obstruction of lymphatics may result in chylothorax and chylous ascites. Obstruction of venules may result in hemosiderosis and hemoptysis.

The frequency of lymphangioliomyomatosis (LAM) is unknown. More than 500 cases are counted in the United States. The prevalence may increase, as the disease becomes better recognized because of increased awareness and better diagnostic techniques.

Earlier reports indicate a pure prognosis with progressive respiratory failure and death within 10 years of diagnosis. Recent reports are more favourable, with 78% of patients who are affected alive at 8.5 years. Women often go undiagnosed for years, and are frequently misdiagnosed with asthma, bronchitis, or emphysema.

Common lymphangioliomyomatosis (LAM) symptoms include dyspnea, manifestations of pneumothorax, cough and less common chest pain, chylothorax, chyluria, pericardial effusion, pneumoperitoneum and lymphedema. Exacerbations of LAM are described during pregnancy, menstruation, and estrogen (ER) use. Physical test is usually normal but less common patients with lymphangioliomyomatosis (LAM) present crackles, wheezes, clubbing, pleural effusion, pneumothorax, ascites.

Chest radiograph findings may appear either normal or with fine reticular or reticulonodular interstitial infiltrate or with delicate honeycombing, pleural effusions and pneumothoraces in more advanced cases. On the other hand, CT scan and HRCT scan findings include diffuse thin-walled cysts which is the defining characteristic appearance in LAM, normal or increased lung volumes, adenopathy and thoracic duct dilatation, pleural effusion, pneumothorax, ground-glass opacities, pulmonary hemorrhage and pericardial

effusion. Up to 50% of women with LAM have a benign kidney tumor called angiomyolipoma.

Differential diagnosis of lymphangiomyomatosis:

- Langerhans cell histiocytosis: >90% are smokers, cysts have irregular shapes and the basal costophrenic angles are spared;
- Centrilobular emphysema: Characterized by airspaces that have no perceptible wall, centrilobular artery seen as dot in the centre;
- Lymphoid interstitial pneumonitis: Seen in patients with HIV and Sjögren syndrome.

References

1. CARSILLO T, ASTRINIDIS A, HENSKE EP. Mutations in the tuberous sclerosis complex gene TSC2 are a cause of sporadic pulmonary lymphangioliomyomatosis. *Proc Natl Acad Sci USA* 2000, 97:6085–6090
2. BOEHLER A, SPEICH R, RUSSI EW, WEDER W. Lung transplantation for lymphangioliomyomatosis. *N Engl J Med* 1996, 335:1275–1280
3. KITAICHI M, NISHIMURA K, ITOH H, IZUMI T. Pulmonary lymphangioliomyomatosis: A report of 46 patients including a clinicopathologic study of prognostic factors. *Am J Respir Crit Care Med* 1995, 151:527–533
4. ADEMA GJ, DE BOER AJ, VOGEL AM, LOENEN WA, FIGDOR CG. Molecular characterization of the melanocyte lineage-specific antigen gp100. *J Biol Chem* 1994, 269:20126–20133
5. BONETTI F, PEA M, MARTIGNONI G, ZAMBONI G, IUZZOLINO P. Cellular heterogeneity in lymphangiomyomatosis of the lung. *Hum Pathol* 1991, 22:727–728
6. CORRIN B, LIEBOW AA, FRIEDMAN PJ. Pulmonary lymphangiomyomatosis. A review. *Am J Pathol* 1975, 79:348–382

Corresponding author:

L. Thanos, Department of Computed Tomography, "Sotiria" General Hospital of Chest Diseases, 152 Mesogeion Ave., GR-115 27 Athens, Greece
e-mail: loutharad@yahoo.com