

CONTINUING MEDICAL EDUCATION ΣΥΝΕΧΙΖΟΜΕΝΗ ΙΑΤΡΙΚΗ ΕΚΠΑΙΔΕΥΣΗ

Internal Medicine Quiz – Case 17

A 31-year-old woman with a medical history of metastatic malignant disease involving the liver and the lungs, was admitted in our clinic due to malaise and fatigue that were rapidly deteriorated. Physical examination revealed skin and conjunctival pallor and sinus tachycardia, as well as an enlarged, nodular, hard, non-tender liver, without splenomegaly.

The complete blood count showed a normochromic, normocytic anemia, leucopenia and a profound thrombocytopenia (tab. 1). Examination of the peripheral blood smear confirmed the results of the complete blood count and showed a slight left shift of the white blood cells. The biochemical profile was notable for a pronounced increase of the serum LDH and ferritin (tab. 1). A bone marrow aspiration was performed. Pictures 1 to 4 show the bone marrow smear of the patient at high magnification.

ARCHIVES OF HELLENIC MEDICINE 2011, 28(2):287–288
ΑΡΧΕΙΑ ΕΛΛΗΝΙΚΗΣ ΙΑΤΡΙΚΗΣ 2011, 28(2):287–288

P.T. Diama ntopoulos,¹
O. Benopoulou,¹
S. Bouros,¹
I. Tsifis,¹
A. Vamvakousis,¹
A. Anastasopoulou,¹
H. Gogas,¹
J. Meletis²

¹First Department of Internal Medicine, National and Kapodistrian University of Athens, School of Medicine, "Laiko" General Hospital, Athens, Greece
²Hematology Department, National and Kapodistrian University of Athens, School of Medicine, "Laiko" General Hospital, Athens

Table 1. Laboratory tests.

Complete blood count						
Ht: 24.2%	Hb: 8.0 g/dL	RBC: $2.7 \times 10^{12}/L$	MCV: 90.7 fL	Ret: 0.41%	PLT: $12 \times 10^9/L$	WBC: $3.5 \times 10^9/\mu L$
Differential: Neutrophils 71%, myelocytes 2%, promyelocytes 2%, lymphocytes 11%, monocytes 11%, eosinophils 1%, baseophils 2%, mature erythroblasts 2/100 WBC						
Biochemical profile						
Glc: 100 mg/dL	BUN: 20 mg/dL	Cr: 0.5 mg/dL	Alb: 2.9 g/dL	LDH: 15,850 U/L	P: 3.0 mg/dL	UA: 3.9 mg/dL
TBil: 1.15 mg/dL	ALP: 1540 IU/L	γ GT: 571 IU/L	ALT: 51 IU/L	AST: 105 IU/L	Fe: 59 μ g/dL	Ferritin: 13,965 ng/mL

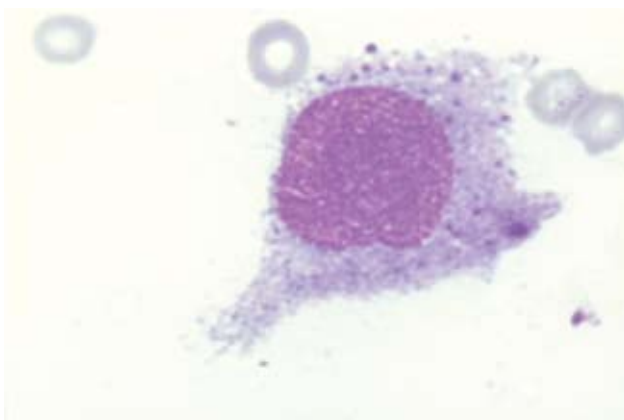


Figure 1

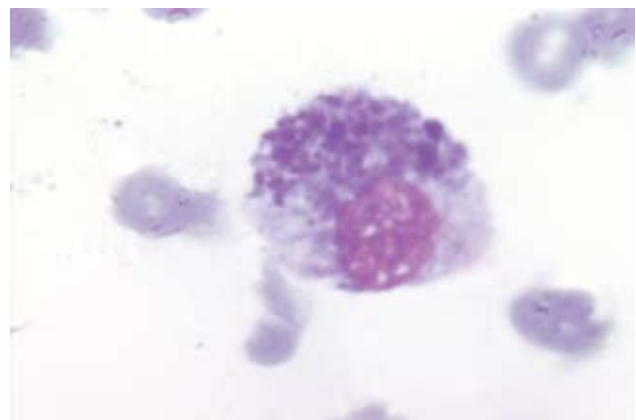


Figure 2

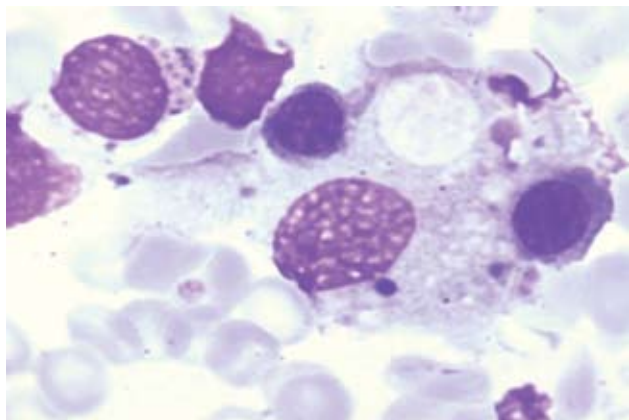


Figure 3

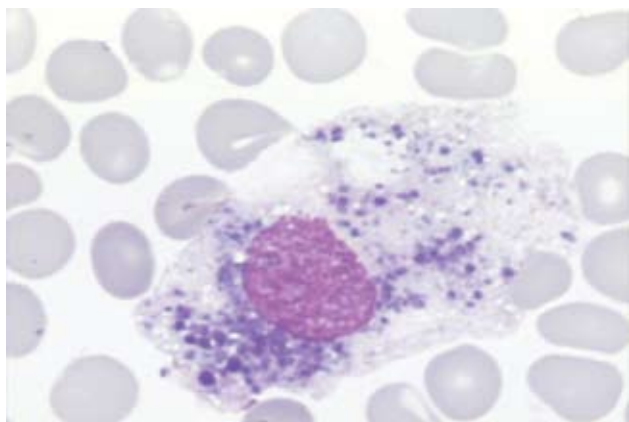


Figure 3

Comment

The emergence of anemia and thrombocytopenia along with a high serum LDH in a patient with a medical history of malignancy and possible generalized metastatic disease may suggest the diagnosis of microangiopathic hemolytic anemia, which is an ominous finding in such patients. Moreover, in the literature, there

are reports of hemophagocytic syndrome in patients with melanoma. Bone marrow infiltration with malignant cells from solid tumors is a poor prognostic sign. Patients with bone marrow metastasis of solid tumors have a median survival of only 5 months.

Metastatic melanoma usually involves the lymph nodes and occasionally the skin and subcutaneous tissue, but eventually metastasizes to distant visceral organs, such as the lungs, brain, and liver. Bone marrow is an uncommon site of melanoma metastasis occurring in about 5% of cases. It usually indicates a widespread metastatic disease, as was the case in our patient that died a few days later.

References

1. BHAGWATI N, SENO R, DUTCHER JP, OLEKSOWICZ L. Fulminant metastatic melanoma complicated by a microangiopathic hemolytic anemia. *Hematopathol Mol Hematol* 1998, 11:101–108
2. CORDEL N, LE CORVAISIER-PIÉTO C, YOUNG P, LENORMAND B, COURVILLE P, SOUBRANE J ET AL. Hemophagocytic syndrome and metastatic melanoma: 3 cases. *Ann Dermatol Venereol* 2000, 127:1077–1079
3. SUN H, WANG GJ, LIU LX, SUN L, ZOU DB, LIU SJ. Analysis of clinical and hematologic features in 22 patients with metastatic carcinoma of bone marrow. *Zhongguo Shi Yan Xue Ye Xue Za Zhi* 2001, 9:307–309
4. SPILLER SE, HAWKINS DS, FINN LS, SZE RW, SYBERT V. Metastatic malignant melanoma presenting as pancytopenia in a three-year-old boy. *Pediatr Blood Cancer* 2005, 45:60–63
5. VILLARRUBIA J, DE MISA RF, ESCRIBANO L, BELLAS C, VELASCO JL. Amelanotic bone marrow infiltration secondary to pigmented malignant melanoma. *J Dermatol* 1995, 22:620–622
6. MELETIS J. *Atlas of hematology*. 3rd ed. Nireas Publ Inc, Athens, 2009:578–600

Corresponding author:

J. Meletis, First Department of Internal Medicine, National and Kapodistrian University of Athens, School of Medicine, "Laiko" General Hospital, Athens, Greece, tel.: +30 210 74 66 206, fax: +30 210 7788830
e-mail: imeletis@med.uoa.gr