

## CONTINUING MEDICAL EDUCATION ΣΥΝΕΧΙΖΟΜΕΝΗ ΙΑΤΡΙΚΗ ΕΚΠΑΙΔΕΥΣΗ

### Thoracic Surgery Quiz – Case 11

A 68-year-old male was referred to our Department with a chief complaint of dysphagia. The physical examination was unremarkable. His medical history included left thyroid lobectomy, thoracic aortic aneurysm repair via median sternotomy and amiodarone administration for treatment of tachyarrhythmia. His laboratory findings were within normal range.

Contrast-enhanced coronal CT scan image demonstrated a globulous, sharply-demarcated lesion to the right of the trachea and oesophagus (fig. 1). The oesophagus appeared to be remarkably compressed by the mass, while the trachea was slightly displaced to the left (fig. 2).

A diagnosis of a diving thyroid gland was made and surgery was decided. The patient underwent total resection of the goiter through a cervical incision and a right posterolateral minimal thoracotomy (fig. 3). This operative strategy was chosen because of the anatomical alterations that previous surgical interventions had established. Partial sternotomy was contraindicated. The substernal mediastinal space was affected due to postoperative fibrosis, neovascularisation and the presence of an aortic graft. Retrotracheal, right paraesophageal and prevertebral dissection led to successful excision.

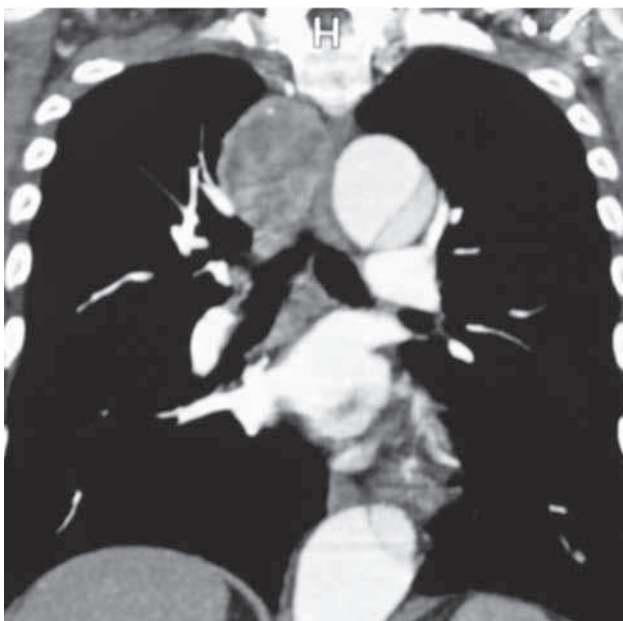


Figure 1

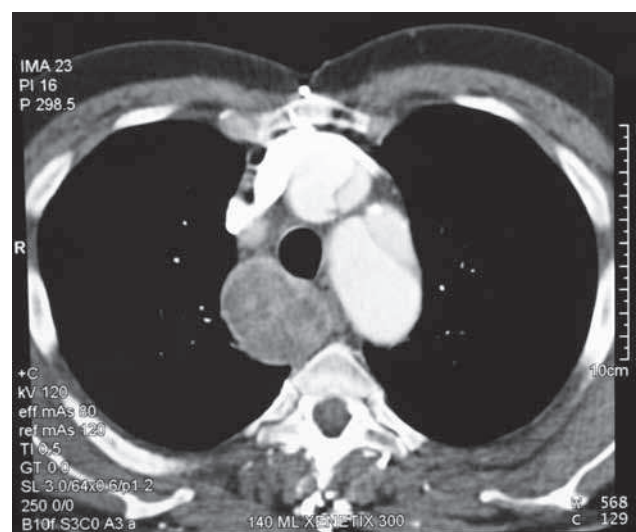


Figure 2

ARCHIVES OF HELLENIC MEDICINE 2013, 30(2):250–252  
ΑΡΧΕΙΑ ΕΛΛΗΝΙΚΗΣ ΙΑΤΡΙΚΗΣ 2013, 30(2):250–252

E. Spartalis,  
P. Charalampoudis,  
C. Kampolis,  
G. Karagkiouzis,  
P. Tomos,  
G. Kouraklis

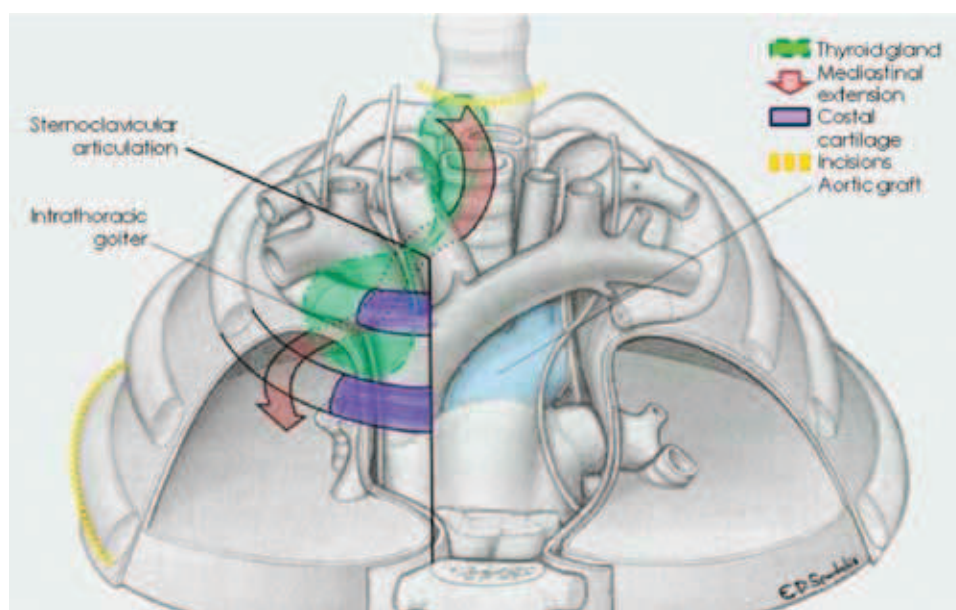
Second Department of Propedeutic  
Surgery, National and Kapodistrian  
University of Athens, Medical School,  
"Laikon" General Hospital of Athens,  
Athens, Greece

Histopathology of the lesion revealed multiple large pieces of thyroid tissue with thyroid follicles of varying size and shape, lined by uniform cuboidal cells. The cells were filled with colloid with some follicles showing cystic macrophages in the lumen.

Postoperative course of the patient was uncomplicated. One year after surgery, he is asymptomatic and disease free.

#### Comment

Most mediastinal goiters are retrosternally situated in the anterior mediastinal compartment. Posterior mediastinal goiters, either retrotracheal or retroesophageal, are rare. Large posterior mediastinal, contralateral retrotracheal or retroesophageal goiters are



**Figure 3**

best removed through a combined cervical and thoracic approach.

It has been reported that skilled head and neck surgeons, with good thyroid surgery experience, need to perform an extra-cervical approach in 2–5% of thyroidectomies for retrotracheal goiters, but some authors have reported an incidence of sternotomy in 29% of patients.

This variability could be correlated with the lack of uniformity in definition of a retrotracheal goiter. Initially, a goiter was generically considered as retro-sternal when extended below the thoracic inlet. Later, retrotracheal goiter was defined by deSouza and Smith as a goiter with a portion of its mass  $\geq 50\%$  situated in the mediastinum. However, this definition lacks anatomic precision and can be interpreted unspecifically. More precise definitions of retrotracheal goiters have been suggested; namely, a goiter lying two fingerbreadths below the thoracic inlet with the patient in a supine position, a goiter reaching the aortic arch, or the carina tracheae, a goiter with its inferior pole passing through the cervico-thoracic isthmus below the subclavian vessels. Several classification systems have also been developed in order to better classify retrotracheal goiters. Cohen and Cho divide goiters into four grades, depending on the percentage of goiter mass located in the mediastinum. Huins et al proposed a classification of retrotracheal goiters based on the relationship of goiter with anatomical structures of the mediastinum: They defined three grades of goiter depending upon mediastinal extension, namely, to the level of the aortic arch, to the level of the pericardium or below the level of the right atrium.

Many attempts have been made to specifically define the factors increasing the likelihood of sternotomy, but a general consensus has still not been reached. Flati et al, in 2005, defined the sternotomic approach as “inevitable” in the presence of an iceberg-shaped retrotracheal goiter with  $>70\%$  of the mass lying in the mediastinum. Later, de Perrot et al, in 2007, highlighted the need to perform a

sternotomy in goiters  $>10$  cm, in patients previously submitted to cervical thyroidectomy, and in the presence of invasive carcinoma or ectopic goiter. Burns et al performed a sternotomy in only 3/140 patients with retrotracheal goiter, since, in their opinion, the most significant factors giving rise to suspicion of the need to perform sternotomy are CT evidence of adherence to the surrounding mediastinal tissues and extension of the goitre to, or below, the aortic arch. More recently, Cohen identified four factors significantly increasing the need to perform sternotomy: (a) The presence of malignancy, (b) involvement of the posterior mediastinum, (c) extension of the goiter below the aortic arch and (d) the presence of ectopic goitre. Cohen et al, suggests that the presence of symptoms is correlated more with the amount of growth of the thyroid at the level of the thoracic inlet, where the tracheae may be more easily compressed by the presence of the sternal manubrium, than by the total mass of the mediastinal thyroid.

Other authors have found that previous thyroid surgery could be a factor increasing the likelihood of sternotomy, due to the frequent finding of adhesences with surrounding tissues. Pre-operative estimation of thyroid volume, by means of CT scan, can be an effective predictor of which patients are likely to require a thoracic approach. However, the final decision as to whether to perform sternotomy can be made only intra-operatively, and the choice is related to the experience of the surgeon. In conclusion, even if retrosternal goiter thyroidectomy is performed by a skilled surgical team, familiar with its unique pitfalls, the assistance of a thoracic surgeon may be required.

## References

1. CHONG CF, CHEAH WK, SIN FL, WONG PS. Posterior mediastinal goiter. *Asian Cardiovasc Thorac Ann* 2004, 12:263–265

2. SHAHIAN DM, ROSSI RL. Posterior mediastinal goiter. *Chest* 1988, 94:599–602
3. WHITE ML, DOHERTY GM, GAUGER PG. Evidence-based surgical management of substernal goiter. *World J Surg* 2008, 32:1285–1300
4. HASHMI SM, PREMACHANDRA DJ, BENNETT AM, PARRY W. Management of retrosternal goitres: Results of early surgical intervention to prevent airway morbidity, and a review of the English literature. *J Laryngol Otol* 2006, 120:644–649
5. COUGARD P, MATET P, GOUDET P, BAMBILI R, VIARD H, VAILLANT B ET AL. Les goitres plongeants: 218 cas operes. *Ann Endocrinol (Paris)* 1992, 53:230–235
6. DeSOUZA FM, SMITH PE. Retrosternal goiter. *J Otolaryngol* 1983, 12:393–396
7. DAHAN M, GAILLARD J, ESCHAPASSE H. Surgical treatment of goiters with intrathoracic development. In: Delarue M (ed) *International trends in general thoracic surgery. Thoracic Surgery: Frontiers and uncommon neoplasms*. Mosby, St Louis, Volume 5, 1989:240–246
8. VADASZ P, KOTSIS L. Surgical aspects of 175 mediastinal goiters. *Eur J Cardiothorac Surg* 1998, 14:393–397
9. SANCHO JJ, KRAIMPS JL, SANCHEZ-BLANCO JM, LARRAD A, RODRÍGUEZ JM, GIL P ET AL. Increased mortality and morbidity associated with thyroidectomy for intrathoracic goiters reaching the carina tracheae. *Arch Surg* 2006, 141:82–85
10. COHEN JP, CHO HT. Surgery for substernal goiters. *Oper Techn Otolaryngol Head Neck Surg* 1994, 5:118–125
11. HUINS CT, GEORGALAS C, MEHRZAD H, TOLLEY NS. A new classification system for retrosternal goitre based on a systematic review of its complications and management. *Int J Surg* 2008, 6:71–76
12. FLATI G, DE GIACOMO T, POROWSKA B, FLATI D, GAJ F, TALARICO C ET AL. Surgical management of substernal goitres. When is sternotomy inevitable? *Clin Ter* 2005, 156:191–195
13. DE PERROT M, FADEL E, MERCIER O, FARHAMAND D, FABRE D, MUSSOT S ET AL. Surgical management of mediastinal goiters: When is a sternotomy required? *Thorac Cardiovasc Surg* 2007, 55:39–43
14. BURNS P, DOODY J, TIMON C. Sternotomy for substernal goitre: An otolaryngologist's perspective. *J Laryngol Otol* 2008, 122:495–499
15. COHEN JP. Substernal goiters and sternotomy. *Laryngoscope* 2009, 119:683–688
16. MONCHIK JM, MATERAZZI G. The necessity for a thoracic approach in thyroid surgery. *Arch Surg* 2000, 135:467–471

*Corresponding author:*

P. Charalampoudis, Second Department of Propedeutic Surgery, National and Kapodistrian University of Athens, Medical School, "Laiko" General Hospital of Athens, Athens, Greece  
e-mail: pcharalampoudis.laiko@gmail.com