

CONTINUING MEDICAL EDUCATION ΣΥΝΕΧΙΖΟΜΕΝΗ ΙΑΤΡΙΚΗ ΕΚΠΑΙΔΕΥΣΗ

Electrocardiogram Quiz – Case 14

A 60-year-old woman presented to the emergency department of our hospital reporting exertional dyspnea and lower extremities' edema of a few days duration. At the emergency department her blood pressure was 85/60 mmHg, oxygen saturation 91% and her body temperature was normal. The 12-lead surface ECG is depicted below.

Questions

- What abnormalities are depicted on the 12-lead ECG (fig. 1)?
- What could be the reason for the above abnormalities?

Comment

Arrhythmogenic right ventricular dysplasia/cardiomyopathy (ARVD/C) is a myocardial disease that primarily affects the right ventricle (RV) and is characterized histologically by the replacement of myocytes by adipose and fibrous tissue. It is usually inherited in an autosomal inherited pattern, with variable expression. Novel

studies showed that point mutations in genes encoding for desmosomal proteins are the main causatives for the development of the disease. Recently it has been shown that mutations in the DES gene could cause ARVD/C. Desmin is an intermediate filament protein, which is linked to the desmosomes. Different DES mutations cause an abnormal aggregation of desmin and associated proteins. The penetrance of the disease is 20–35% in general, but significantly higher in Italy. Seven gene loci have been implicated in ARVD/C. However, about 50% of families which express ARVD/C

ARCHIVES OF HELLENIC MEDICINE 2013, 30(6):753–754
ΑΡΧΕΙΑ ΕΛΛΗΝΙΚΗΣ ΙΑΤΡΙΚΗΣ 2013, 30(6):753–754

E. Petrou,
I. Fekos,
A. Tsipis,
M. Boutsikou,
V. Vartela,
I. Rassias,
A. Kostopoulou,
E. Livanis,
G. Theodorakis

Division of Cardiology, "Onassis" Cardiac
Surgery Center, Athens, Greece

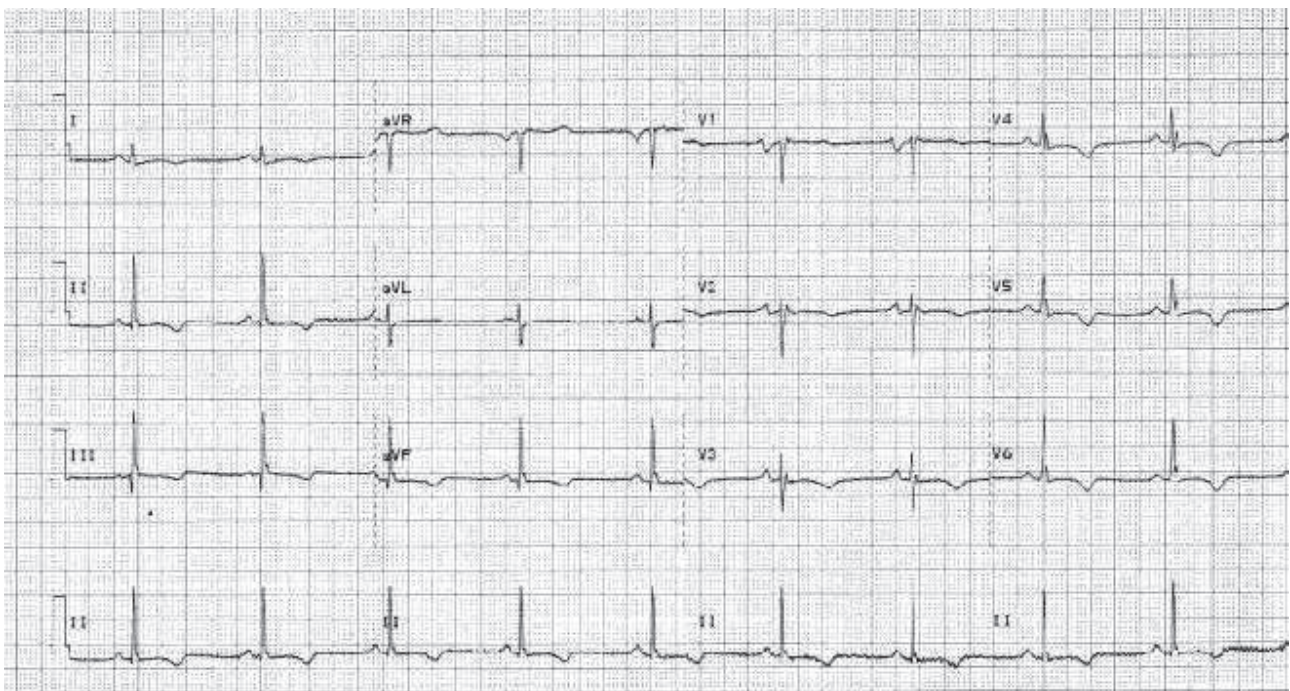


Figure 1

that undergo genetic screening do not show linkage with any of the known chromosomal loci. It is unclear whether the pathogenesis varies with the different loci involved. Standard genetic screening tests are currently performed and evaluated in different state of the art cardiovascular research centres and hospitals. Up to 80% of individuals with ARVD/C present with syncope or sudden cardiac death. The remainder frequently present with palpitations or other symptoms due to right ventricular outflow tract tachycardia (a type of monomorphic ventricular tachycardia). Symptoms are usually exercise-related. There is no pathognomonic feature of ARVD/C. The diagnosis is based on a combination of major and minor history, imaging and ECG criteria.

The anatomic damage present in ARVD/C modifies electrical activation and repolarization, particularly of the RV. Almost 90% of patients with ARVD/C present with some ECG abnormality. Several ECG features of the disease have been included in the criteria for the diagnosis of ARVD/C, as described by the Task Force on Right Ventricular Myopathies of the European Society of Cardiology. These criteria include (a) T-wave inversions in V1 through V3 (in the absence of complete RBBB), (b) QRS duration (QRSd) ≥ 110 ms in V1 through V3 (which has been observed in 24–70% of patients, representing a delayed activation of the RV rather than an intrinsic abnormality in the right bundle branch), and (c) the presence of an epsilon wave (electric potentials after the end of the QRS complex found in 30–33% of patients) (fig. 2). Additional ECG markers of




Figure 2

ARVD/C that have been reported include (a) QRS and QT dispersion, (b) parietal block, defined as a QRSd in leads V1 through V3 that exceeds the QRSd in lead V6 by >25 ms, and (c) a ratio of the QRSd in leads $V1+V2+V3/V4+V5+V6 \geq 1.2$.

The main goal of management of ARVD/C is to decrease the incidence of sudden cardiac death. Therapeutic interventions include pharmacological agents, catheter ablation, implantable cardioverter-defibrillators (ICDs) and cardiac transplantation. Our patient underwent an uncomplicated ICD implantation and was discharged with explicit instructions and medication.

References

1. MARCUS FI, FONTAINE GH, GUIRAUDON G, FRANK R, LAURENCEAU JL, MALERQUE C ET AL. Right ventricular dysplasia: A report of 24 adult cases. *Circulation* 1982, 65:384–398
2. CORRADO D, BASSO C, THIENE G, MCKENNA WJ, DAVIES MJ, FONTALIRAN F ET AL. Spectrum of clinicopathologic manifestations of arrhythmogenic right ventricular cardiomyopathy/dysplasia: A multicenter study. *J Am Coll Cardiol* 1997, 30:1512–1520
3. NASIR K, BOMMA C, TANDRI H, ROGUIN A, DALAL D, PRAKASA K ET AL. Electrocardiographic features of arrhythmogenic right ventricular dysplasia/cardiomyopathy according to disease severity: A need to broaden diagnostic criteria. *Circulation* 2004, 110:1527–1534
4. JAIN R, DALAL D, DALY A, TICHNELL C, JAMES C, EVENSON A ET AL. Electrocardiographic features of arrhythmogenic right ventricular dysplasia. *Circulation* 2009, 120:477–487

Corresponding author:

E.G. Petrou, Division of Cardiology, "Onassis" Cardiac Surgery Center, 356 Sygrou Ave., GR-176 74 Kallithea, Greece
e-mail: emmgpetrou@hotmail.com