

CONTINUING MEDICAL EDUCATION ΣΥΝΕΧΙΖΟΜΕΝΗ ΙΑΤΡΙΚΗ ΕΚΠΑΙΔΕΥΣΗ

Hematology Quiz – Case 38

An 80-year-old man presented to the outpatient clinic with fatigue, difficulty in breathing, heartburn, chest pain and palpitations in effort, pain in fingers and toes during last week and hemorrhagic dermal rash, especially in the lower extremities (fig. 1). There was a history of mild anemia and attacks of acrocyanosis (blue discoloration of fingers and toes following exposure in cold) for the last ten years. A chronic, non-paramorphotic arthritis of the hands was diagnosed ten years ago with mild cervical lymphadenopathy and mild splenomegaly. No abnormal findings were detected in the CT of upper and lower abdomen, and of the chest.

Physical examination revealed pallor, tachycardia, splenomegaly (2 cm below the left costal margin), and hepatomegaly (one centimeter below the right costal margin). Mild cervical and axillar lymphadenopathy were detected. Physical examination was otherwise unremarkable.

Laboratory tests were as follows: Hct=21.3%, Hb=6.1 g/dL, WBC=2,800/ μ L (neutrophils 38%, lymphocytes 50%, monocytes 12%), reticulocytes=6.1% and platelets=144.000/ μ L. Peripheral blood smears is shown in figures 2 and 3. Blood chemistry was Glu=1.50 mg/dL, BUN=0.70 mg/dL, creatinine=0.9 mg/dL, Na⁺=135 mmol/L, K⁺=4.0 mmol/L, Ca⁺⁺=4.6 mEq/L, SGOT=26 IU/L, SGPT=16 IU/L, bilirubin=2.52 mg/dL (indirect 1.8 mg/dL), ALP=105 IU/L, γ GT=32 IU/l, uric acid=5.5 mg/dL, LDH=1,070 IU/L, CPK=10 IU/L. Total protein was 7.3 g/L (alb=3 g/L, α_1 -globulins=0.3,

α_2 -globulins=0.3, β -globulins=0.7 and γ -globulins=2.5 g/L). The coagulation tests were normal (PT=11 sec, APTT=30 sec, fibrinogen=230 mg/dL). Direct Coombs test was positive for IgG, IgA, IgM, and C3: indirect Coombs test was also positive. Antibodies for *Mycoplasma*, EBV and other viruses were negative. ANA, anti-DNA tests were positive. Urine chemistry and microscopy were normal.

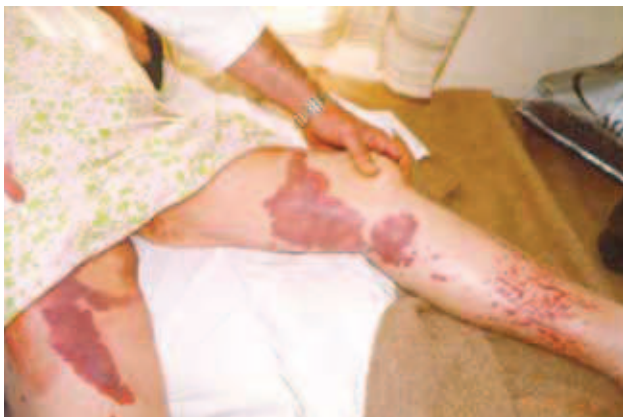

Figure 1

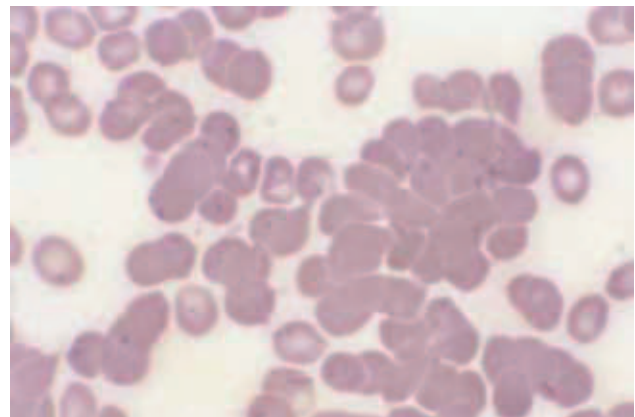


Figure 2

ARCHIVES OF HELLENIC MEDICINE 2015, 32(1):114–115
ΑΡΧΕΙΑ ΕΛΛΗΝΙΚΗΣ ΙΑΤΡΙΚΗΣ 2015, 32(1):114–115

**J. Asimakopoulos,
L. Papageorgiou,
K. Petevi,
G. Boutsikas,
G. Gainarou,
P. Flevari,
E. Koutsi,
V. Telonis,
A. Zannou,
P. Tsaftaridis,
E. Plata,
T.P. Vassilakopoulos,
M.K. Angelopoulou,
K. Konstantopoulos,
J. Meletis**

Hematology Department and Bone Marrow Transplantation Unit, National and Kapodistrian University of Athens, School of Medicine, "Laikon" General Hospital, Athens

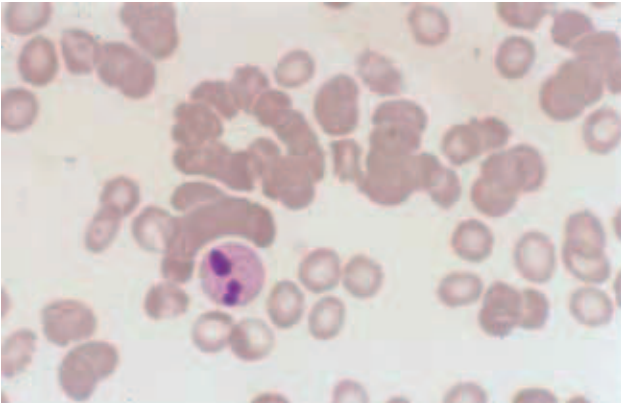


Figure 3

References

1. SOKOL RJ, BOOKER DJ, STAMPS R, WALEWSKA R. Cold haemagglutinin disease: Clinical significance of serum haemolysins. *Clin Lab Haematol* 2000, 22:337–344
2. PANWAR U, MATHEWS C, CULLIS JO. Cost-effectiveness of rituximab in refractory cold agglutinin disease. *Int J Lab Hematol* 2008, 30:331–333
3. MELETIS J. *Atlas of hematology*. 3rd ed. Nireas Publ Inc, Athens, 2009:259, 270–274

Corresponding author:

J. Meletis, Hematology Department and Bone Marrow Transplantation Unit, National and Kapodistrian University of Athens, School of Medicine, “Laiko” General Hospital, Athens, Greece, Tel.: +30 210 74 66 902, Fax: +30 210 7456698
e-mail: imeletis@med.uoa.gr