

## CONTINUING MEDICAL EDUCATION ΣΥΝΕΧΙΖΟΜΕΝΗ ΙΑΤΡΙΚΗ ΕΚΠΑΙΔΕΥΣΗ

### Medical Imaging Quiz – Case 43

A middle aged woman presented to us in the outdoor of Govt. Medical College and Guru Nanak Dev Hospital, Amritsar to get treatment for hepatitis C infection. She was supposed to undergo elective surgery for cholelithiasis but was detected to be reactive for hepatitis C. During her work-up for the same, incidental detection of hepatic along with splenic cysts was made on ultrasonography of the abdomen. The splenic cyst was septate and daughter cysts were also present (figures 1, 2).

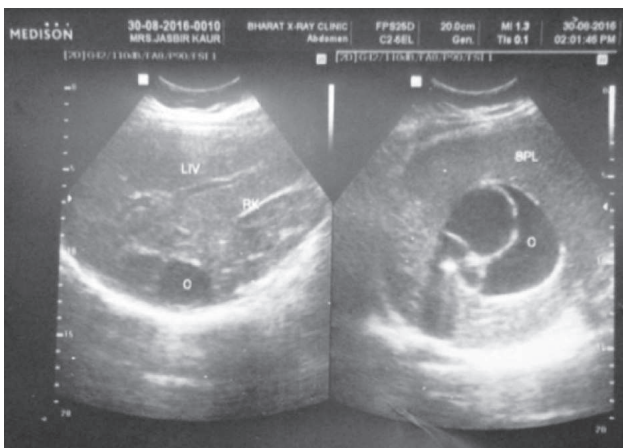


Figure 1

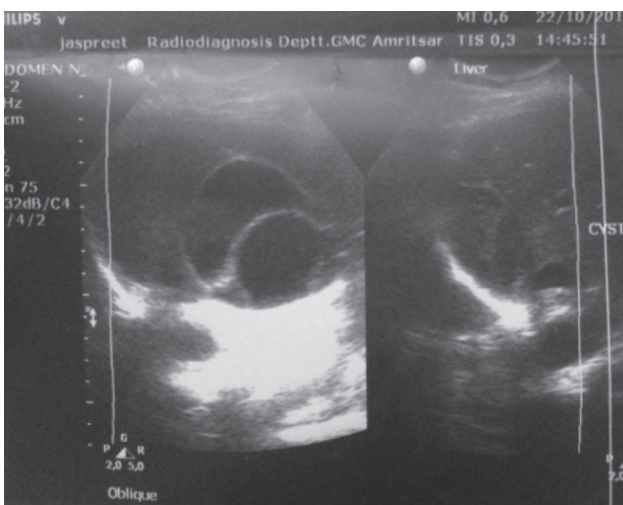


Figure 2

ARCHIVES OF HELLENIC MEDICINE 2017, 34(2):276–277  
ΑΡΧΕΙΑ ΕΛΛΗΝΙΚΗΣ ΙΑΤΡΙΚΗΣ 2017, 34(2):276–277

N.S. Neki,<sup>1</sup>  
G.S. Shergill,<sup>1</sup>  
A. Singh,<sup>1</sup>  
A. Kaur,<sup>2</sup>  
S. Nizami,<sup>3</sup>  
D. Kaushal<sup>1</sup>

<sup>1</sup>Department of Medicine, Government Medical College and Guru Nanak Dev Hospital, Amritsar

<sup>2</sup>Civil Hospital, Fatehgarh Sahib, Punjab

<sup>3</sup>Department of Surgery, Mata Gujari Memorial Medical College and LSK hospital, Kishanganj, Bihar, India

#### Comment

Hydatid cyst or cystic echinococcosis (CE) is a condition of livestock and humans that arises from eating infective eggs of the cestode *Echinococcus granulosus*. Dogs are the primary definitive hosts for this parasite, with livestock acting as intermediate hosts and humans as aberrant intermediate hosts. Once the parasite passes through the intestinal wall to reach the portal venous system or lymphatic system, the liver acts as the first line of defence and is therefore the most frequently involved organ. The spleen is a rare location for hydatid cysts with the larvae reaching the site after escaping the hepatic and pulmonary filters. The reported prevalence of splenic involvement in hydatid disease varies from 0.9% to 8%. Splenic hydatid disease is mainly produced by systemic dissemination or intraperitoneal spread from a ruptured liver cyst. The most frequent clinical signs and symptoms are abdominal pain, splenomegaly, and fever.

Splenic hydatid cysts are usually solitary, and their imaging characteristics are similar to those of hepatic hydatid cysts. Cyst wall calcification may occur and is better depicted at computed tomography (CT) than at radiography or ultrasonography. CT may demonstrate the typical high-attenuation linear wall without calcification, as well as daughter vesicles within the cyst.

Treatment is reserved for symptomatic cases. Medical treatment is done with albendazole or mebendazole. Surgery remains the complete cure and is the cornerstone therapy. Although splenectomy has been the conventional treatment of choice for splenic hydatidosis as it aims at eradicating the disease while decreasing the chances of recurrence by removing the intact cyst. While this is true, the risk of other endemic parasitic infections like malaria and babesiosis is increased. Laparoscopic approach for uncomplicated hydatid cyst of the liver and spleen is a safe and effective option.

## References

1. KING CH. Cestodes (tapeworms). In: Mandell GL, Bennett JE, Dolin R (eds) *Principles and practice of infectious diseases*. 4th ed. Churchill Livingstone, New York, NY, 1995:2544–2553
2. BEGGS I. The radiology of hydatid disease. *AJR Am J Roentgenol* 1985, 145:639–648
3. ABU-ESHY SA. Some rare presentations of hydatid cyst (*Echinococcus granulosus*). *J R Coll Surg Edinb* 1998, 43:347–352
4. FRANQUET T, MONTES M, LECUMBERRI FJ, ESPARZA J, BESCOS JM. Hydatid disease of the spleen: Imaging findings in nine patients. *AJR Am J Roentgenol* 1990, 154:525–528
5. VON SINNER WN, STRIDBECK H. Hydatid disease of the spleen: Ultrasonography, CT and MR imaging. *Acta Radiol* 1992, 33:459–461
6. KHOURY G, ABIAD F, GEAGEAT, NABOUT G, JABBOUR S. Laparoscopic treatment of hydatid cysts of the liver and spleen. *Surg Endosc* 2000, 14:243–245

Corresponding author:

N.S Neki, #88, Street number 4, Gopal Nagar, Majitha Road, Amritsar, 143001, Punjab, India  
e-mail: drneki123@gmail.com