

## CASE REPORT ΕΝΔΙΑΦΕΡΟΥΣΑ ΠΕΡΙΠΤΩΣΗ

# Ramipril-induced acute pancreatitis A case report and literature review

It is estimated that 1.4–2% of cases of acute pancreatitis are drug induced. Drug-induced pancreatitis is usually mild to moderate in severity, but rare cases of fulminant drug-induced acute pancreatitis have been reported. The case is presented of a patient with acute pancreatitis due to ramipril, an angiotensin-converting enzyme inhibitor. Discontinuation of the drug usually leads to disappearance of symptoms and normalization of the biochemical and radiological parameters of acute pancreatitis, as in this case.

ARCHIVES OF HELLENIC MEDICINE 2017, 34(6):821–823  
ΑΡΧΕΙΑ ΕΛΛΗΝΙΚΗΣ ΙΑΤΡΙΚΗΣ 2017, 34(6):821–823

N. Vallianou,<sup>1</sup>  
E. Geladari,<sup>1</sup>  
K. Trigkidis,<sup>1</sup>  
A. Skoula,<sup>2</sup>  
E. Kokkinakis<sup>1</sup>

<sup>1</sup>First Department of Internal Medicine,  
“Evangelismos” General Hospital, Athens

<sup>2</sup>Department of Radiology,  
“Evangelismos” General Hospital,  
Athens, Greece

Παγκρεατίτιδα επαγόμενη από  
τη χορήγηση ραμιπρίλης: Κλινική  
περίπτωση και ανασκόπηση της  
βιβλιογραφίας

Περίληψη στο τέλος του άρθρου

### Key words

Angiotensin-converting enzyme  
inhibitor  
Drug-induced pancreatitis  
Ramipril

Submitted 25.11.2016  
Accepted 8.12.2016

### INTRODUCTION

Drug-induction is estimated to be the cause of acute pancreatitis in 1.4–2% of cases. Drug-induced pancreatitis is usually mild to moderate in severity and tends to disappear after drug discontinuation, but rare cases of fulminant drug-induced acute pancreatitis have been reported.<sup>1</sup> The case is presented of a patient with acute pancreatitis caused by the use of ramipril, an angiotensin-converting enzyme inhibitor.

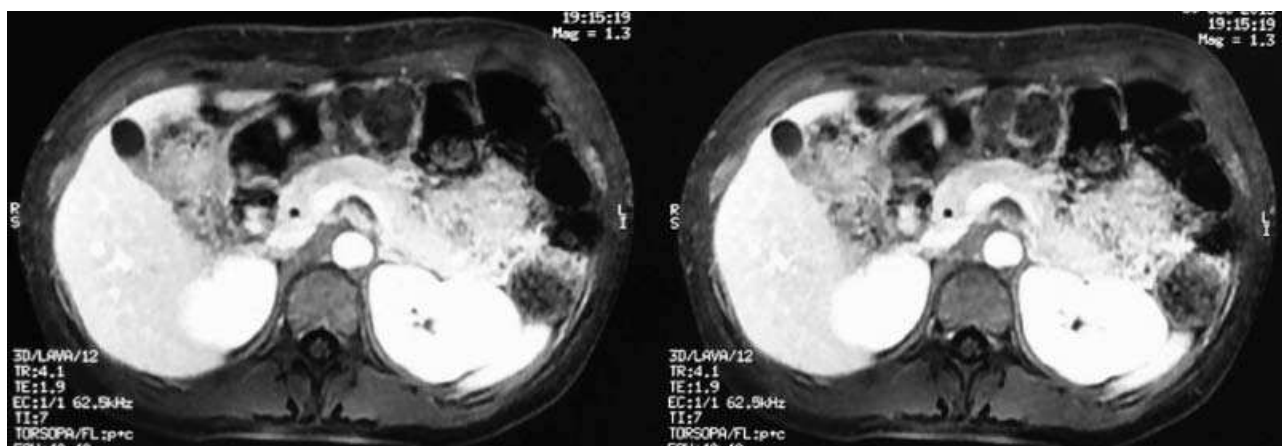
### CASE PRESENTATION

A 37-year-old female with type 1 diabetes mellitus (DM) and recently diagnosed nephrotic syndrome presented at the emergency department with epigastric pain which radiated to her back, accompanied by nausea and vomiting. The symptoms had begun two weeks earlier, but had worsened over the last 4 days. The patient did not drink alcohol or use any illegal drugs.

The laboratory tests were normal, apart from raised serum amylase (697 U/L), and urine amylase (1,926 U/L). The serum levels of triglycerides and IgG4 were within the normal range. Abdominal magnetic resonance imaging (MRI) revealed enlargement in the body and the tail of the pancreas, along with opacification of the peri-pancreatic tissue, findings compatible with pancreatitis (fig. 1). Neither abdominal ultrasound (US) nor the MRI showed any gallstones. Drug-induced pancreatitis was suspected. The patient had been taking ramipril, an angiotensin-converting enzyme inhibitor, at a dose of 2.5 mg/day for 4 weeks, because of the occurrence of nephrotic syndrome. Ramipril was stopped and candesartan 16 mg/day was administered for the nephrotic syndrome. The symptoms disappeared, and the patient was discharged from the hospital with serum and urine amylase levels within the normal range and free of abdominal symptoms. She remains asymptomatic 3 months after her hospitalization.

### COMMENTS

Ramipril-induced pancreatitis has been reported only



**Figure 1.** Abdominal magnetic resonance imaging (MRI) in a 37-year-old female with epigastric pain, depicting enlargement of the body and the tail of the pancreas, and opacification of the surrounding tissues.

three times,<sup>1-3</sup> although other angiotensin-converting enzyme inhibitors have been associated with acute pancreatitis.<sup>3-8</sup> Angiotensin II receptor blockers have been associated with pancreatitis very rarely;<sup>9,10</sup> specifically, 3 cases with losartan, 2 with imbesartan and one with telmisartan have been recorded. Angiotensin-converting enzyme inhibitors are known to affect the kallikrein-kinin system, resulting in intrapancreatic accumulation of bradykinin, thought to be caused by pancreatitis.<sup>11</sup> Angiotensin receptor blockers have no effect on the kallikrein-kinin system and thus the mechanism by which they cause pancreatitis remains un-

clear. In experimental animal models, the administration of angiotensin receptor blockers decreases pancreatic damage and improves the biochemical and histopathological parameters of pancreatitis.<sup>12,13</sup>

In conclusion, in the absence of other apparent causes, angiotensin-converting enzyme inhibitors should be sought as a cause of acute pancreatitis. Discontinuation of the drug usually leads to disappearance of symptoms and normalization of the biochemical and radiological parameters of acute pancreatitis.

## ΠΕΡΙΛΗΨΗ

### Παγκρεατίτιδα επαγόμενη από τη χορήγηση ραμιπρίλης: Κλινική περίπτωση και ανασκόπηση της βιβλιογραφίας

N. ΒΑΛΛΙΑΝΟΥ,<sup>1</sup> Ε. ΓΕΛΑΔΑΡΗ,<sup>1</sup> Κ. ΤΡΙΓΚΙΔΗΣ,<sup>1</sup> Α. ΣΚΟΥΛΑ,<sup>2</sup> Ε. ΚΟΚΚΙΝΑΚΗΣ<sup>1</sup>

<sup>1</sup>Α΄ Παθολογική Κλινική, Γενικό Νοσοκομείο Αθηνών «Ο Ευαγγελισμός», Αθήνα, <sup>2</sup>Ακτινολογικό Τμήμα, Γενικό Νοσοκομείο Αθηνών «Ο Ευαγγελισμός», Αθήνα

Αρχεία Ελληνικής Ιατρικής 2017, 34(6):821-823

Η επαγόμενη από φάρμακα παγκρεατίτιδα είναι υπεύθυνη για το 1,4-2% των περιπτώσεων παγκρεατίτιδας γενικά. Συνήθως είναι ήπιας ή μέτριας βαρύτητας. Παρ' όλα αυτά, υπάρχουν σπάνιες περιπτώσεις κεραυνοβόλου παγκρεατίτιδας επαγόμενης από φάρμακα. Στο παρόν άρθρο παρουσιάζεται περίπτωση οξείας παγκρεατίτιδας μετά από χορήγηση ραμιπρίλης, ενός αναστολέα του μετατρεπτικού ενζύμου της αγγειοτασίνης. Η διακοπή του φαρμάκου οδηγεί ως επί το πλείστον σε υποχώρηση των συμπτωμάτων της παγκρεατίτιδας και σε επάνοδο στο φυσιολογικό των βιοχημικών παραμέτρων και των ακτινολογικών ευρημάτων της παγκρεατίτιδας.

**Λέξεις ευρητήριο:** Αναστολέας του μετατρεπτικού ενζύμου της αγγειοτασίνης, Παγκρεατίτιδα επαγόμενη από φάρμακα, Ραμιπρίλη

## References

1. KANBAY M, KORKMAZ M, YILMAZ U, GUR G, BOYACIOGLU S. Acute pancreatitis due to ramipril therapy. *Postgrad Med J* 2004, 80:617–618
2. VINKLEROVÁ I, PROCHÁZKA M, PROCHÁZKA V, URBÁNEK K. Incidence, severity, and etiology of drug-induced acute pancreatitis. *Dig Dis Sci* 2010, 55:2977–2981
3. SINGH S. Angiotensin-converting enzyme (ACE) inhibitor-induced pancreatitis: In search of the evidence. *South Med J* 2006, 99:1327–1328
4. BEDROSSIAN S, VAHID B. A case of fatal necrotizing pancreatitis: Complication of hydrochlorothiazide and lisinopril therapy. *Dig Dis Sci* 2007, 52:558–560
5. ELAND IA, SUNDSTRÖM A, VELO GP, ANDERSEN M, STURKENBOOM MC, LANGMAN MJ ET AL. Antihypertensive medication and the risk of acute pancreatitis: The European case-control study on drug-induced acute pancreatitis (EDIP). *Scand J Gastroenterol* 2006, 41:1484–1490
6. FAMULARO G, MINISOLA G, NICOTRA GC, DE SIMONE C. Idiosyncratic pancreatitis associated with perindopril. *JOP* 2005, 6:605–607
7. DOUROS A, BRONDER E, ANDERSON F, KLIMPEL A, THOMAE M, OCKENGA J ET AL. Drug-induced acute pancreatitis: Results from the hospital-based Berlin case-control surveillance study of 102 cases. *Aliment Pharmacol Ther* 2013, 38:825–834
8. STANDRIDGE JB. Fulminant pancreatitis associated with lisinopril therapy. *South Med J* 1994, 87:179–181
9. CAN B, SALI M, BATMAN A, YILMAZ H, KORKMAZ U, CELEBI A ET AL. Valsartan-induced acute pancreatitis. *Intern Med* 2014, 53:703–705
10. BIRCK B, KEIM V, FIEDLER F, VAN DER WOUDE FJ, ROHMEISS P. Pancreatitis after losartan. *Lancet* 1998, 351:1178
11. GRIESBACHER T, LEMBECK F. Effects of the bradykinin antagonist, HOE 140, in experimental acute pancreatitis. *Br J Pharmacol* 1992, 107:356–360
12. TSANG SW, CHENG CH, LEUNG PS. The role of the pancreatic renin-angiotensin system in acinar digestive enzyme secretion and in acute pancreatitis. *Regul Pept* 2004, 119:213–219
13. ORUC N, OZUTEMIZ O, NART D, YUCE G, CELIK HA, ILTERT. Inhibition of renin-angiotensin system in experimental acute pancreatitis in rats: A new therapeutic target? *Exp Toxicol Pathol* 2010, 62:353–360

Corresponding author:

N.G. Vallianou, 5 Pyramidon street, GR-190 05 Marathonas, Greece  
e-mail: natalia.vallianou@hotmail.com

.....