

CONTINUING MEDICAL EDUCATION ΣΥΝΕΧΙΖΟΜΕΝΗ ΙΑΤΡΙΚΗ ΕΚΠΑΙΔΕΥΣΗ

Vascular Diseases Quiz – Case 46

A 34-year-old female presented with left leg swelling and feeling of heaviness. These symptoms first appeared a couple of years earlier after she gave birth to her third child. Swelling worsened when the patient was standing for a long time or when the leg was dependent, while the leg returned to almost normal when she was laying on the bed. Otherwise, the patient was fit and well. Previous ultrasound scans for deep vein thrombosis were negative. Stemmer sign was negative.

What is a probable diagnosis and what imaging method is best to set that diagnosis?

Comment

May-Thurner syndrome (MTS), also known as iliac vein compression syndrome is a rare condition in the left iliac vein which is compressed by the overlying right iliac artery (fig. 1). This compression leads to pooling of the venous flow, predisposing the patient to thrombosis. Fibrous spurs also develop at the stenotic location, as a result of the pulsatile force of the artery. Symptoms vary widely from totally asymptomatic to leg swelling, pain, heaviness, claudication and deep vein thrombosis.

Diagnosis is usually set by computed tomography (CT) or magnetic resonance (MR) venography. Classic venography has lower sensitivity and specificity compared to these two modern imaging methods, and should be used only in specific cases (fig. 2). Ultrasound scanning of the pelvis is technically challenging, but in experienced hands ultrasound could provide valuable information.

Modern therapy consists of vein angioplasty and stenting under intra-venous ultrasound (IVUS) guidance. Thrombolysis should be

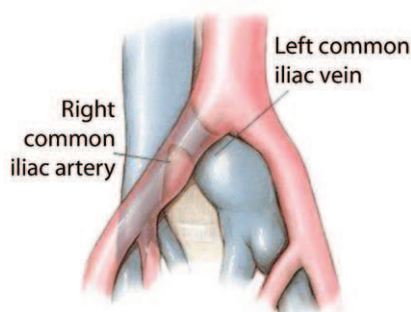


Figure 1. Anatomy of May-Thurner syndrome (MTS).

ARCHIVES OF HELLENIC MEDICINE 2018, 35(2):279
ΑΡΧΕΙΑ ΕΛΛΗΝΙΚΗΣ ΙΑΤΡΙΚΗΣ 2018, 35(2):279

**N. Patelis,
C. Klonaris**

First Department of Surgery, Vascular Unit, "Laiko" General Hospital, Medical School, National and Kapodistrian University of Athens, Athens, Greece

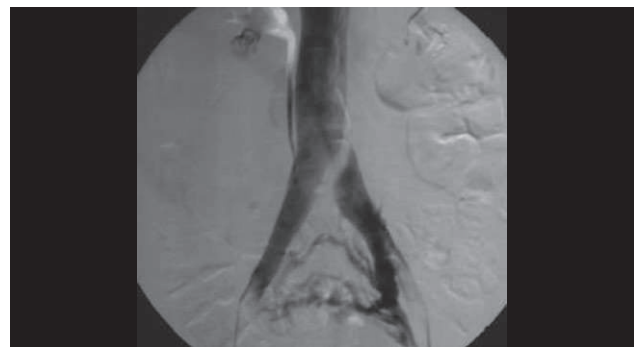


Figure 2. Venography of May-Thurner syndrome (MTS) case.

considered if iliac thrombosis is present. Surgical iliac reconstruction is now less frequently used.

References

1. MAY R, THURNER J. The cause of the predominantly sinistral occurrence of thrombosis of the pelvic veins. *Angiology* 1957, 8:419–427
2. LABROPOULOS N, BORGE M, PIERCE K, PAPPAS PJ. Criteria for defining significant central vein stenosis with duplex ultrasound. *J Vasc Surg* 2007, 46:101–107
3. JOST CJ, GLOVICZKI P, CHERRY KJ Jr, MCKUSICK MA, HARMSSEN WS, JENKINS GD ET AL. Surgical reconstruction of iliofemoral veins and the inferior vena cava for nonmalignant occlusive disease. *J Vasc Surg* 2001, 33:320–327
4. SUWANABOL PA, TEFERA G, SCHWARZE ML. Syndromes associated with the deep veins: Phlegmasia cerulea dolens, May-Thurner syndrome, and nutcracker syndrome. *Perspect Vasc Surg Endovasc Ther* 2010, 22:223–230

Corresponding author:

C. Klonaris, First Department of Surgery, Vascular Unit, "Laiko" General Hospital, Medical School, National and Kapodistrian University of Athens, 115 27 Athens, Greece
e-mail: chris_klonaris@yahoo.com

Diagnosis: May-Thurner syndrome; CT or MR venography