

## CASE REPORT ΕΝΔΙΑΦΕΡΟΥΣΑ ΠΕΡΙΠΤΩΣΗ

### Rare observation of retinal vasculopathy in a young patient with primary dengue

A young patient presented with fever for two days and a week later from onset of fever, patient noticed a blurring of vision in both the eyes. Hemogram showed a platelet count of 108,000/ $\mu$ L. Dengue fever was diagnosed based on dengue serology (positive for immunoglobulin IgM). Fundus fluorescein angiography (FFA) showed bilateral dilated, tortuous vessels with retinal hemorrhages and capillary occlusion suggestive of retinal vasculopathy. Patient was treated with a course of oral steroids for five days and symptomatic improvement in visual symptoms was noted. Ocular involvement in dengue is diverse and tends to occur five to seven days after onset of fever during the nadir of thrombocytopenia. Overall, dengue-related ocular complications have a good prognosis.

Dengue is a mosquito-borne infectious disease caused by one of the four antigenically related serotypes of dengue virus. Dengue virus belongs to the Flavivirus genus and family Flaviviridae.<sup>1</sup> Globally, 70% of the overall disease burden is represented by Asian countries. Infection is transmitted to humans by bites of infected *Aedes* mosquitoes. Its manifestations range from a mild flu-like illness to dengue hemorrhagic fever and dengue shock syndrome. Primary dengue is usually a self-limiting illness whereas severe systemic complications are associated with secondary dengue. Infection with one serotype confers lifelong immunity against that particular serotype but immunity against other serotypes by cross reactive antibodies is weak and non-protective.<sup>1</sup> Ophthalmic manifestations in dengue are uncommon and diversified. We intend to highlight a rare complication of retinal vasculopathy due to dengue microangiopathy.

#### CASE PRESENTATION

A young patient with no underlying medical comorbid illness presented with sudden onset bilateral blurring of vision with metamorphopsia for one day and headache for 7 days. One week prior to onset of visual symptoms, the patient had a fever associated with chills and rigor, which lasted for two days and loose stools and vomiting for a day. Patient had a bifrontal headache, moderate in intensity (4/10 score on numeric rating scale), intermittent in nature, not associated with projectile vomiting and responded to tablet acetaminophen. Patient did not have any other symptoms like cough, sputum production, dysuria, bleeding manifestations, joint pain or swelling, double vision, altered sensorium. Patient did not have any previous history of dengue illness. On examination, blood pressure was 120/80 mmHg, pulse rate was 82/min, respiratory rate was 20/min, temperature was 98 °F. Patient did not have any skin rash, petechiae or purpura on the trunk or extremities. Systemic examination was unremarkable. No hepatosplenomegaly or lymphadenopathy noted.

ARCHIVES OF HELLENIC MEDICINE 2024, 41(3):423–426  
ΑΡΧΕΙΑ ΕΛΛΗΝΙΚΗΣ ΙΑΤΡΙΚΗΣ 2024, 41(3):423–426

S. Koruprolu,<sup>1</sup>  
V. Pandurangan,<sup>1</sup>  
S. Varadan,<sup>1</sup>  
R.B. Sudagar Singh,<sup>1</sup>  
S. Sudhakar<sup>2</sup>

<sup>1</sup>Department of General Medicine,  
Sri Ramachandra Institute of Higher  
Education and Research, Porur, Chennai

<sup>2</sup>Department of Ophthalmology, Sri  
Ramachandra Institute of Higher  
Education and Research, Porur, Chennai,  
India

Σπάνια περίπτωση αγγειοπάθειας  
αμφιβληστροειδούς σε νεαρό με  
δάγγειο πυρετό

Περίληψη στο τέλος του άρθρου

#### Key words

Dengue  
Retinal vasculitis  
Thrombocytopenia  
Vasculopathy

Submitted 29.10.2023

Accepted 11.11.2023

Ophthalmology examination showed no congestion/chemosis in conjunctiva, no subconjunctival hemorrhage, visual acuity of 6/9 and normal near vision (N6) in both eyes and normal anterior chamber depth, no cells, no hemorrhage. Colour vision and Amsler's grid test were normal in both the eyes. Direct and indirect light reflex was intact in both the eyes. Swinging flashlight test showed no evidence of relative apparent pupillary defect in both the eyes. Extraocular movements were intact in both the eyes. Fundus examination of right eye showed clear vitreous, normal optic disc, normal macula, dilated tortuous vessels with flame-shaped hemorrhage in papillomacular bundle in right eye and early flame shaped hemorrhages near optic disc with cotton wool spots and dot and blot hemorrhages temporal to the macula in the left eye. Table 1 shows the laboratory findings including fever work up.

Differential diagnosis considered were (a) Dengue vasculopathy, (b) vasculitis secondary to connective tissue disease (CTD), (c) idiopathic retinal vasculitis. Since patient had retinal hemorrhages despite normal coagulation parameters and platelet count of 108,000/ $\mu\text{L}$ , thromboelastography (TEG) was done and it showed low reaction time (R, clot initiation time) of 1.8 min (4–8 minutes normal value) and normal maximum amplitude [MA], signifying clot strength and platelet aggregation) of 71.6 mm (54–72 mm normal value). Hence, retinal hemorrhage and ocular findings were attributed to retinal vasculopathy secondary to dengue microangiopathy. Fundus fluorescein angiography (FFA) showed occlusion of capillary leading to the vein in the papillomacular bundle corresponding to the flame shaped hemorrhage in the right eye, occlusion of capillary temporal to the macula corresponding to the dot and blot hemor-

**Table 1.** Laboratory results including fever work up.

Test	Patient value	Reference range
<i>Hemogram:</i>		
Hemoglobin	14 g/dL	12–15 g/dL
White cell count	5,500/ $\mu\text{L}$	4,000–11,000/ $\mu\text{L}$
Platelet count	108,000/ $\mu\text{L}$	150,000–450,000/ $\mu\text{L}$
<i>Liver function test:</i>		
Total bilirubin	0.40 mg/dL	0.2–1.2 mg/dL
Alanine aminotransferase (ALT)	215 IU/L	0–41 IU/L
Aspartate aminotransferase (AST)	236 IU/L	0–35 IU/L
<i>Coagulation panel:</i>		
Prothrombin time (test)	9.9	10.9–13.1 seconds
Prothrombin time (control)	12.0	–
International normalized ratio (INR)	0.87	–
Activated partial thromboplastin time	28	27–40 seconds
<i>Fever panel work up:</i>		
Dengue IgM by ELISA	49	>11 IgM units, positive
Dengue IgG by ELISA	1.71	>11 IgG units, positive
MP QBC and rapid malarial antigen	Negative	–
Leptospirosis IgM	Negative	–
Scrub typhus IgM	Negative	–
Blood culture	No growth	–
Urine culture	No growth	–
<i>Viral markers:</i>		
Hepatitis B surface antigen	Non-reactive	–
Anti-hepatitis C virus antibodies	Negative	–
HIV I and II antibodies with p24 antigen	Negative	–
VDRL	Negative	–
<i>Acute phase reactants:</i>		
Erythrocyte sedimentation rate (ESR)	8 mm/hour	4–19 mm/hour
C reactive protein (CRP)	0.1	0–0.8 mg/dL
<i>Mantoux (tuberculin skin test), read at 72 hours</i>	3 mm induration	>10 mm reactive

VDRL test: Venereal disease research laboratory test

rhage in the left eye, and both eyes had dilated, tortuous vessels. Optical coherence testing (OCT) showed normal foveal contour and normal central macular thickness in both eyes. Figure 1 shows the fundus picture, FFA and OCT of the right and left eye.

Connective tissue disease and vasculitis work up to rule out any coexisting autoimmune disease was negative which included anti-nuclear antibody (ANA), IgM rheumatoid factor (RF), anti-cyclic-citrullinated-peptide (anti-CCP) antibodies, direct Coombs test, line immunoassay for extractable nuclear antigens (LIA), antineutrophil cytoplasmic antibodies (p-ANCA, c-ANCA).

Diagnosis of primary dengue with retinal vasculopathy was made based on fundus findings, dengue serology being positive for immunoglobulin M (IgM) and negative for IgG and FFA showing blocked fluorescence corresponding to the area of hemorrhage and cotton-wool spot.

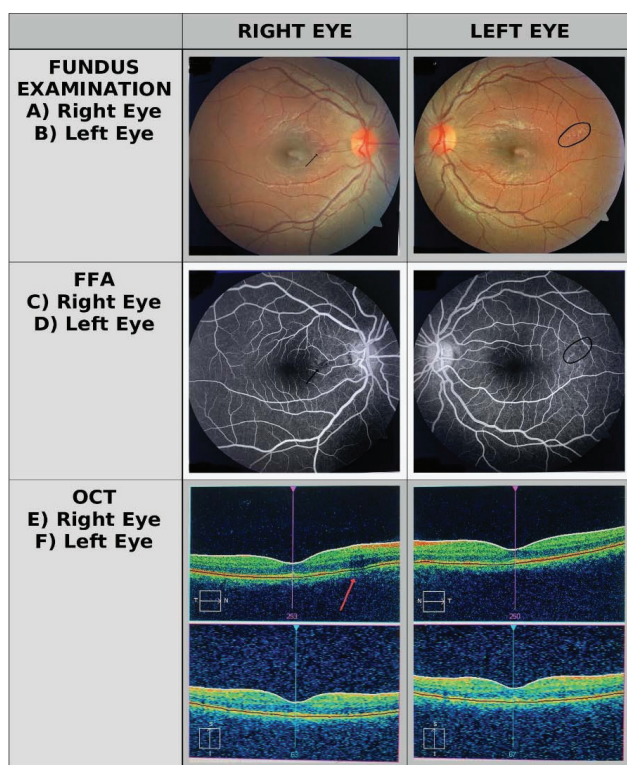
Visual evoked potential (VEP) showed delayed p100 response suggestive of slowed conduction in optic nerve. Hence to rule out

optic neuritis, serum neuromyelitis optica antibodies (NMO) and magnetic resonance imaging (MRI) of brain with contrast were done and which were negative. Antiphospholipid antibodies were negative.

Patient was treated symptomatically with intravenous fluids (0.9% saline), tablet pantoprazole 40 mg and tablet acetaminophen 500 mg. Platelet count was monitored daily and on discharge platelet count was 161,100/ $\mu$ L. In view of retinal vasculopathy with slowed conduction in the optic nerve, the patient was given a short course of oral steroids (tablet prednisolone 40 mg/day for 5 days). The patient had significant improvement in visual symptoms and ocular fundus findings had no progression, and reported complete resolution of visual symptoms over telephonic follow-up, four weeks later from discharge from hospital.

## DISCUSSION

Ocular manifestations of dengue occur usually five to seven days after onset of fever.<sup>2</sup> Posterior segment involvement is seen more often than involvement of anterior segment in dengue. The most common ocular symptom reported was blurring of vision followed by scotoma. Other symptoms include metamorphopsia, micropsia, impaired color vision, floaters. Scotoma corresponds to regions of macular edema and hemorrhages.<sup>3</sup> Diverse ophthalmic manifestations reported were subconjunctival hemorrhages, maculopathy, foveolitis, uveitis, retinal vasculopathy, optic neuropathy, and vitritis. Ocular complications coincide with nadir of thrombocytopenia.<sup>2</sup> The pathophysiologic mechanisms of dengue-related ophthalmic complications are not well understood and thought to be due to immune-mediated, since the manifestations mostly occur after seven days of symptom onset when thrombocytopenia reaches its nadir.<sup>4,5</sup> Eye is an immune privileged organ and hence protected from systemic effects of inflammation due to various infections. Dengue virus to cause ocular damage requires breach of the blood retinal barrier which comprises retinal pigment epithelium (RPE) and endothelium. Studies have shown that dengue virus shows tropism for retinal pigment epithelium (RPE) and endothelium. Dengue virus causes cytopathic effects on RPE and increased intercellular permeability disrupting the blood retinal barrier.<sup>6</sup> Dengue retinopathy include retinal vasculopathy with either apparent or subclinical retinal vasculitis, retinal hemorrhages, and retinal vascular occlusion. Foveolitis, though less common, is a characteristic feature of dengue. Age, sex, ethnicity does not have correlation with ocular manifestations of dengue. Seet et al observed total leucocyte count and serum albumin levels as significant predictors of ocular symptoms in patients with dengue fever.<sup>7</sup> Other factors associated with ocular complications include serotype of dengue virus, geography, viral virulence. Dengue vi-



**Figure 1.** Fundus picture, fundus fluorescein angiography (FFA) and optical coherence testing (OCT) of the right and left eye. (A) Right eye fundus – superficial hemorrhages in the papillomacular bundle area with mild arteriolar narrowing in the capillaries. (B) Left eye fundus – superficial hemorrhages with mild retinal edema with capillary occlusion in the supero-temporal macular arcade (C) Right eye FFA – shows capillary non-perfusion and thinning and blocked fluorescence, corresponding to vasculopathy area. (D) Left eye FFA – shows capillary occlusion with blocked fluorescence in the supero-temporal arcade. (E) Right eye OCT – shows normal fovea thickness and contour and areas of superficial hemorrhages nasal to the fovea. (F) Left eye OCT – shows normal fovea thickness and contour and areas of superficial hemorrhages temporal to the fovea.

rus serotype 1 was found to be associated with dengue maculopathy.<sup>3</sup> Most patients with dengue vasculopathy have a good visual recovery and carry better prognosis though recovery time varies from weeks to three months.<sup>8</sup> Dengue maculopathy with cystoid macular edema carries a poor visual prognosis and visual acuity of those patients remains to be poor. Bilateral presentation with severe visual loss and severe retinal vasculitis are treated with systemic steroids and may require intravenous immunoglobulins.<sup>9</sup>

Unusual observations in our patient: (a) Retinal vasculopathy in our patient occurred not during nadir of thrombocytopenia rather when the platelet count was in recovery phase (platelet count: 108,000/ $\mu$ L on admission) and (b)

secondary dengue causes more severe complications. In our patient, retinal vasculopathy, a rare complication occurred due to primary dengue related microangiopathy.

## CONCLUSIONS

Dengue-related ocular complications can be life-threatening. Primary care physicians treating tropical infections in endemic areas should have a high index of suspicion regarding the ocular complications in patients with dengue reporting visual complaints. Dengue-related ocular manifestations occur during the nadir of thrombocytopenia and overall have a good prognosis.

## ΠΕΡΙΛΗΨΗ

### Σπάνια περίπτωση αγγειοπάθειας αμφιβληστροειδούς σε νεαρό με δάγγειο πυρετό

S. KORUPROLU,<sup>1</sup> V. PANDURANGAN,<sup>1</sup> S. VARADAN,<sup>1</sup> R.B. SUDAGAR SINGH,<sup>1</sup> S. SUDHAKAR<sup>2</sup>

<sup>1</sup>Department of General Medicine, Sri Ramachandra Institute of Higher Education and Research, Porur, Chennai,

<sup>2</sup>Department of Ophthalmology, Sri Ramachandra Institute of Higher Education and Research, Porur, Chennai, Ινδία

*Αρχεία Ελληνικής Ιατρικής 2024, 41(3):423–426*

Νεαρός ασθενής παρουσίασε πυρετό για δύο ημέρες και μία εβδομάδα αργότερα παρατήρησε θόλωση της όρασης και στα δύο μάτια. Η γενική αίματος έδειξε αριθμό αιμοπεταλίων 108.000/ $\mu$ L. Διαγνώστηκε δάγγειος πυρετός με βάση τις ορολογικές εξετάσεις (θετικός για IgM ανοσοσφαιρίνη). Η ψηφιακή φλουροαγγειογραφία (FFA) έδειξε αμφοτερόπλευρα διεσταλμένα, ελικοειδή αγγεία με αιμορραγίες του αμφιβληστροειδούς και απόφραξη τριχοειδών, χαρακτηριστικά αγγειοπάθειας. Ο ασθενής υποβλήθηκε σε θεραπεία με από του στόματος χορήγηση στεροειδών για 5 ημέρες και παρατηρήθηκε συμπτωματική βελτίωση στα οπτικά συμπτώματα. Η οφθαλμική συμμετοχή στον δάγγειο πυρετό ποικίλλει και τείνει να εμφανίζεται 5–7 ημέρες μετά την έναρξη του πυρετού κατά τη διάρκεια του ναδίου της θρομβοπενίας. Συνολικά, οι οφθαλμικές επιπλοκές που σχετίζονται με τον δάγγειο πυρετό έχουν καλή πρόγνωση.

**Λέξεις ευρητηρίου:** Αγγειίτιδα του αμφιβληστροειδούς, Αγγειοπάθεια, Δάγγειος πυρετός, Θρομβοπενία

## References

- KOK BH, LIM HT, LIM CP, LAI NS, LEOW CY, LEOW CH. Dengue virus infection – a review of pathogenesis, vaccines, diagnosis and therapy. *Virus Res* 2023, 324:199018
- NG AW, TEOH SC. Dengue eye disease. *Surv Ophthalmol* 2015, 60:106–114
- CHEE E, SIMS JL, JAP A, TAN BH, OH H, CHEE SP. Comparison of prevalence of dengue maculopathy during two epidemics with differing predominant serotypes. *Am J Ophthalmol* 2009, 148:910–913
- LIM WK, MATHUR R, KOH A, YEOH R, CHEE SP. Ocular manifestations of dengue fever. *Ophthalmology* 2004, 111:2057–2064
- SU DHW, BACSAL K, CHEE SP, FLORES JVP, LIM WK, CHENG BCL ET AL. Prevalence of dengue maculopathy in patients hospitalized for dengue fever. *Ophthalmology* 2007, 114:1743–1747
- CARR JM, ASHANDER LM, CALVERT JK, MA Y, ALOIA A, BRACHO GG ET AL. Molecular responses of human retinal cells to infection with dengue virus. *Mediators Inflamm* 2017, 2017:3164375
- SEET RC, QUEK AM, LIM EC. Symptoms and risk factors of ocular complications following dengue infection. *J Clin Virol* 2007, 38:101–105
- SOMKIJRUNGROJ T, KONGWATTANANON W. Ocular manifestations of dengue. *Curr Opin Ophthalmol* 2019, 30:500–505
- AGARWAL L, AGRAWAL N. Retinal vasculitis with macular infarction: A dengue-related ophthalmic complication. *Int Med Case Rep J* 2020, 13:363–366

*Corresponding author:*

V. Pandurangan, Department of General Medicine, Sri Ramachandra Institute of Higher Education and Research, Porur, Chennai, Tamil Nadu, 600116 India  
e-mail: viswa.smc@gmail.com